US00D975120S

(12) United States Design Patent

Barnard et al.

(10) Patent No.: US D975,120 S
(45) Date of Patent: ** Jan. 10, 2023

(54) **DISPLAY SCREEN OR PORTION THEREOF WITH GRAPHICAL USER INTERFACE FOR MODIFYING A REPORT WITH AN ABSTRACTION TOOL**

(71) Applicant: **Roche Molecular Systems, Inc.**, Pleasanton, CA (US)

(72) Inventors: **Cindy K. Barnard**, Santa Clara, CA (US); **Sambasivarao Byrapuneni**, Pleasanton, CA (US); **Diwakar Chapagain**, Cupertino, CA (US); **Archana P. Dorge**, Campbell, CA (US); **Catherine M. Jeu**, San Jose, CA (US); **Rengaraja Kesavan**, Pleasanton, CA (US); **Kaushal D. Parekh**, Redwood City, CA (US); **Raman Ramanathan**, San Jose, CA (US); **David M. Schlossman**, Columbia, MO (US); **Vishakha Sharma**, Foster City, CA (US)

(73) Assignee: **Roche Molecular Systems, Inc.**, Pleasanton, CA (US)

(**) Term: **15 Years**

(21) Appl. No.: **29/766,576**

(22) Filed: **Jan. 15, 2021**

(51) **LOC (14) Cl.** **14-04**

(52) **U.S. Cl.**
USPC **D14/486**

(58) **Field of Classification Search**
USPC D14/485–495
(Continued)

(56) **References Cited**

U.S. PATENT DOCUMENTS

D733,176 S * 6/2015 Lin D14/486
D809,530 S * 2/2018 Matheson D14/485
(Continued)

Primary Examiner — Sheryl Lane
Assistant Examiner — Nicole C Shiflet
(74) *Attorney, Agent, or Firm* — Kilpatrick Townsend and Stockton LLP

(57) **CLAIM**

The ornamental design for a display screen or portion thereof with graphical user interface for modifying a report with an abstraction tool, as shown and described.

DESCRIPTION

FIG. **1** is a front view of a first image in a sequence of a display screen or portion thereof with graphical user interface for modifying a report with an abstraction tool showing our new design;
FIG. **2** is a front view of a second image thereof;
FIG. **3** is a front view of a third image thereof;
FIG. **4** is a front view of a fourth image thereof;
FIG. **5** is a front view of a fifth image thereof;
FIG. **6** is a front view of a sixth image thereof;
FIG. **7** is a front view of a seventh image thereof;
FIG. **8** is a front view of an eighth image thereof;
FIG. **9** is a front view of a ninth image thereof;
FIG. **10** is a front view of a tenth image thereof;
FIG. **11** is a front view of an eleventh image thereof;
FIG. **12** is a front view of a twelfth image thereof;
FIG. **13** is a front view of a thirteenth image thereof;
FIG. **14** is a front view of a fourteenth image thereof; and,
FIG. **15** is a front view of a fifteenth image thereof.
The outermost broken lined rectangles indicate a boundary of a display screen or a portion thereof and form no part of the claimed design. The broken lined text and characters form no part of the claimed design.
The appearance of the animated images sequentially transition from FIG. **1** to FIG. **15**. The process or period in which one image transitions to another forms no part of the claimed design.

1 Claim, 15 Drawing Sheets

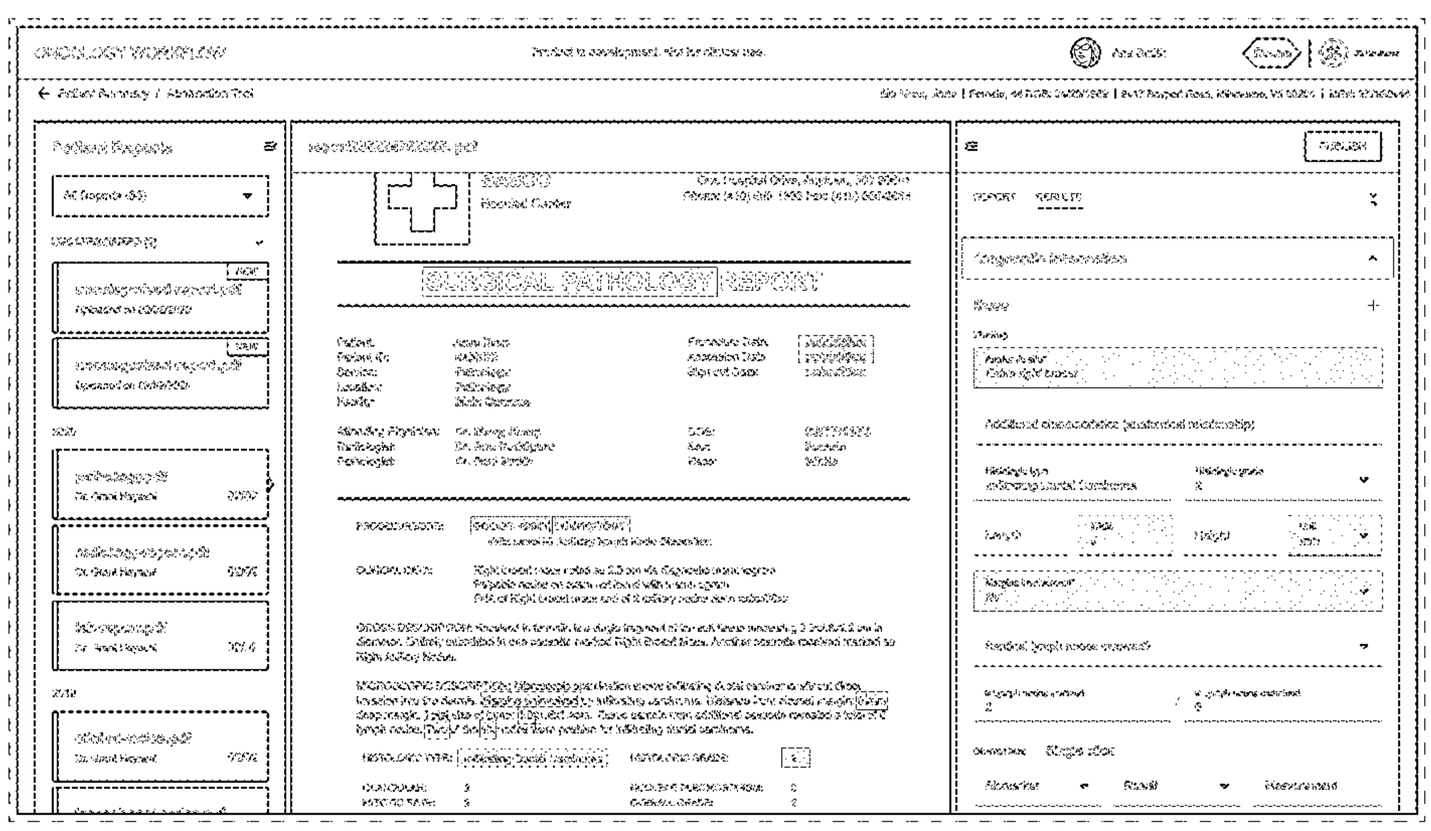

(58) **Field of Classification Search**
CPC G06F 3/048; G06F 3/0481; G06F 3/04817; G06F 3/0482; G06F 3/0483; G06F 3/04842; G06F 3/0485; G06F 3/04855; G06F 3/0486; G06F 3/0488; G06F 3/04886; G06F 9/451; G06F 40/103; G06F 40/106; G06F 40/189; G06F 40/191
See application file for complete search history.

(56) **References Cited**

U.S. PATENT DOCUMENTS

D836,652	S	*	12/2018	Fowler	D14/486
D841,031	S	*	2/2019	Orlando	D14/486
D860,238	S	*	9/2019	Bhardwaj	D14/488
D868,104	S	*	11/2019	Christiana	D14/488
D871,443	S	*	12/2019	Christiana	D14/488
D874,481	S	*	2/2020	Kumar	D14/485
D881,211	S	*	4/2020	Marohn	D14/486
D888,739	S	*	6/2020	Christiana	D14/486
D890,199	S	*	7/2020	Kumar	D14/486
D892,849	S	*	8/2020	Sharma	D14/488
D902,226	S	*	11/2020	Burnell	D14/486
D905,734	S	*	12/2020	Christiana	D14/488
D906,360	S	*	12/2020	Eissa	D14/488
D922,420	S	*	6/2021	Castle	D14/486
D930,022	S	*	9/2021	Xie	D14/486
D931,314	S	*	9/2021	Xie	D14/486
D936,078	S	*	11/2021	Singh	D14/485
D940,172	S	*	1/2022	Xie	D14/486
2016/0349949	A1	*	12/2016	Miller	G06F 16/328
2019/0391825	A1	*	12/2019	Jann	G06F 3/0482

* cited by examiner

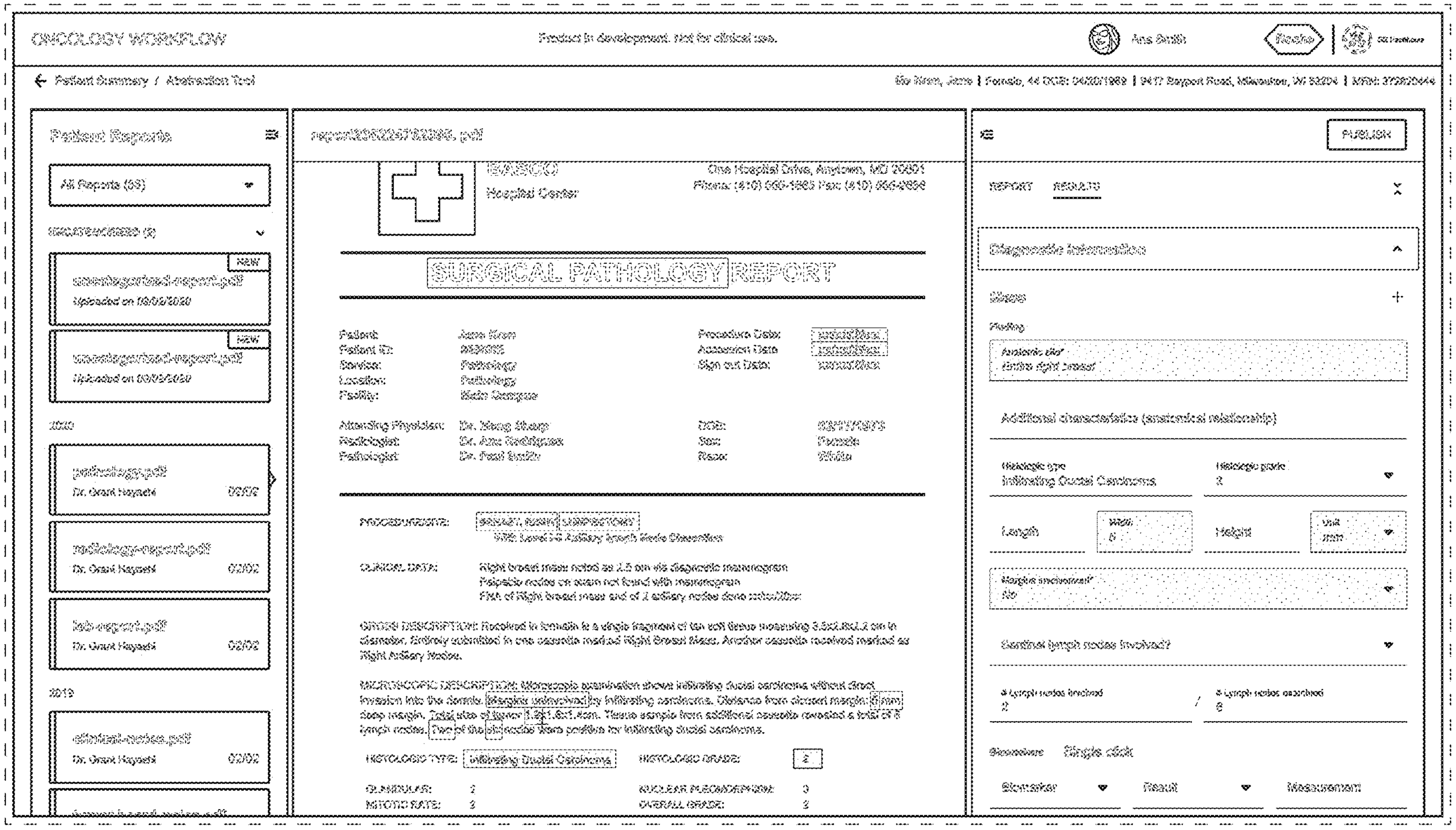
ONCOLOGY WORKFLOW
Product in development. Not for clinical use.
Ana Smith
Roche
Patient Summary / Abstraction Tool
Patient Reports
All Reports (53)
NEW
uncategorized-report.pdf
Uploaded on 10/03/2020
NEW
uncategorized-report.pdf
Uploaded on 10/03/2020
2020
pathology.pdf
Dr. Grant Hayashi 02/02
radiology-report.pdf
Dr. Grant Hayashi 02/02
lab-report.pdf
Dr. Grant Hayashi 02/02
2019
sentinel-nodes.pdf
Dr. Grant Hayashi 02/02
report20302257622884.pdf
BASCO
Hospital Center
One Hospital Drive, Anytown, MD 20801
SURGICAL PATHOLOGY REPORT
Patient: Jane Krom
Patient ID: 8829385
Service: Pathology
Location: Pathology
Facility: Main Campus
Procedure Date:
Accession Date:
Sign out Date:
Attending Physician: Dr. Meng Sharp
Radiologist: Dr. Ana Rodriguez
Pathologist: Dr. Paul Smith
DOB:
Sex: Female
Race: White
PROCEDURE(S):
CLINICAL DATA:
GROSS DESCRIPTION:
MICROSCOPIC DESCRIPTION:
HISTOLOGIC TYPE: Infiltrating Ductal Carcinoma
HISTOLOGIC GRADE: 2
GLANDULAR: 2
MITOTIC RATE: 2
NUCLEAR PLEOMORPHISM: 3
OVERALL GRADE: 2
PUBLISH
REPORT
RESULTS
Diagnostic Information
Biopsy
Finding
Anatomic site
Entire right breast
Additional characteristics (anatomical relationship)
Histologic type
Infiltrating Ductal Carcinoma
Histologic grade
2
Length
Width
6
Height
Unit
mm
Margins involved?
No
Sentinel lymph nodes involved?
Lymph nodes involved
2
Lymph nodes examined
6
Biomarkers
Single click
Biomarker
Result
Measurement

FIG. 1

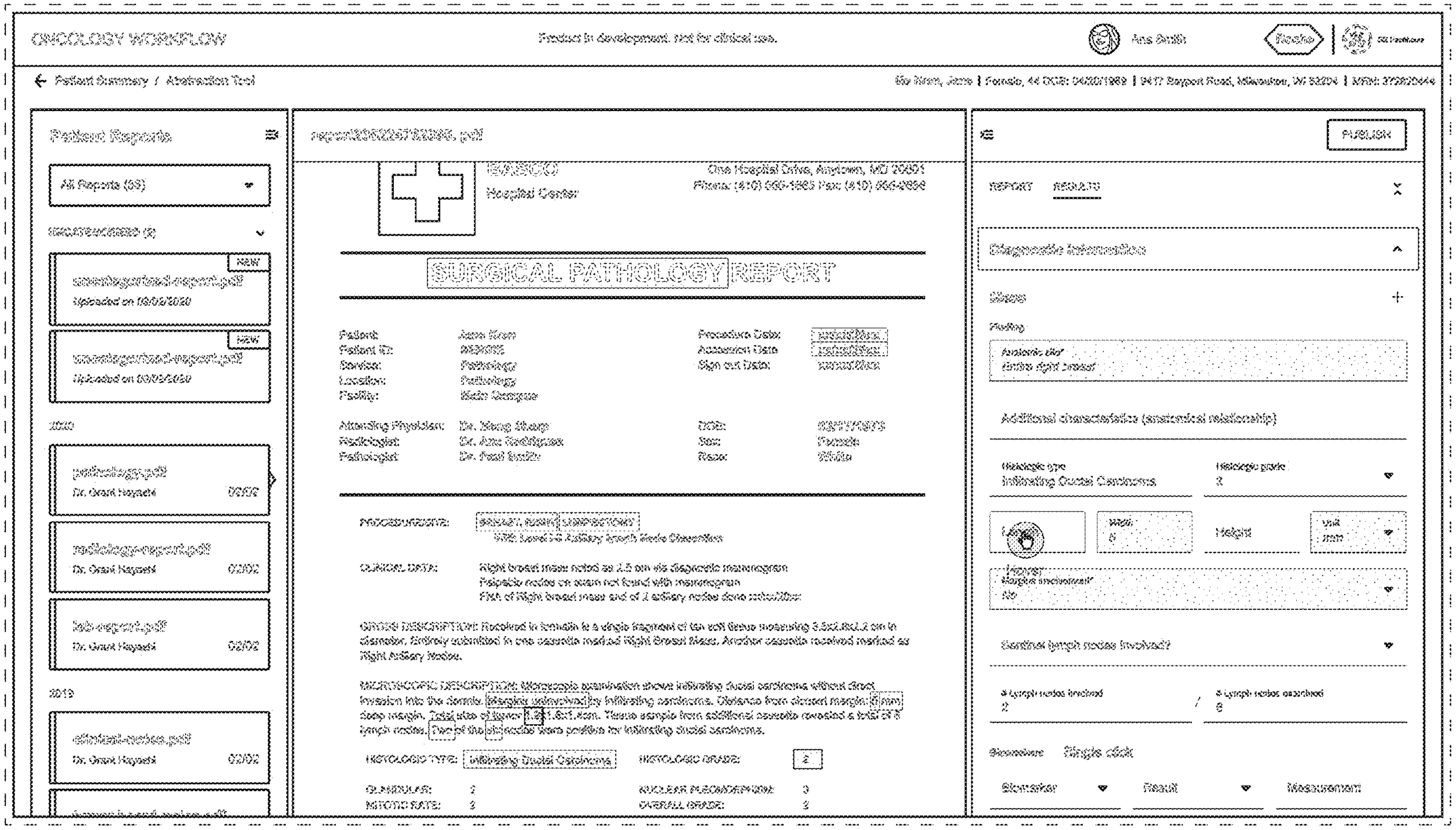
ONCOLOGY WORKFLOW
Product in development. Not for clinical use.
Ana Smith
Patient Summary / Abstraction Tool
Patient Reports
All Reports (53)
NEW
uncategorized-report.pdf
Uploaded on 10/03/2020
NEW
uncategorized-report.pdf
Uploaded on 10/03/2020
2020
pathology.pdf
Dr. Grant Hayashi 02/02
radiology-report.pdf
Dr. Grant Hayashi 02/02
lab-report.pdf
Dr. Grant Hayashi 02/02
2019
sentinel-nodes.pdf
Dr. Grant Hayashi 02/02
report20522257622864.pdf
BASCO
Hospital Center
SURGICAL PATHOLOGY REPORT
PUBLISH
REPORT
RESULTS
Diagnostic Information
Blocks
Additional characteristics (anatomical relationship)
Sentinel lymph nodes involved?
Biomarker
Result
Measurement

FIG. 2

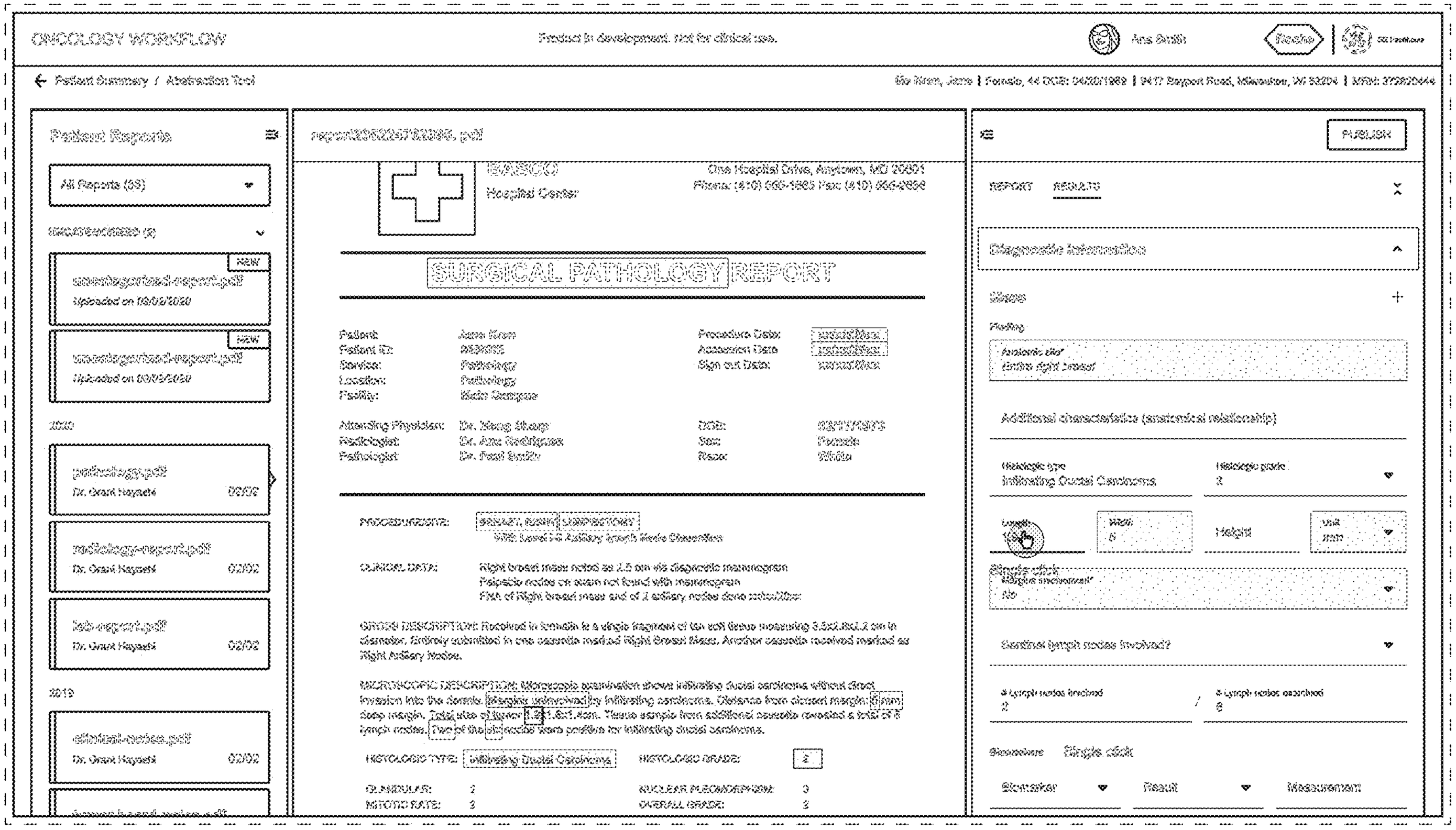
ONCOLOGY WORKFLOW
Product in development. Not for clinical use.
Ana Smith
Roche
Patient Summary / Abstraction Tool
Patient Reports
All Reports (53)
NEW
uncategorized-report.pdf
Uploaded on 10/03/2020
NEW
uncategorized-report.pdf
Uploaded on 10/03/2020
2020
pathology.pdf
Dr. Grant Hayashi 02/02
radiology-report.pdf
Dr. Grant Hayashi 02/02
lab-report.pdf
Dr. Grant Hayashi 02/02
2019
sentinel-nodes.pdf
Dr. Grant Hayashi 02/02
report20522257622864.pdf
BASCO
Hospital Center
One Hospital Drive, Anytown, MD 20601
SURGICAL PATHOLOGY REPORT
Patient: Jane Krom
Patient ID: 8829385
Service: Pathology
Location: Pathology
Facility: Main Campus
Procedure Date:
Accession Date
Sign out Date:
Attending Physician: Dr. Meng Sharp
Radiologist: Dr. Ana Rodriguez
Pathologist: Dr. Paul Smith
DOB:
Sex: Female
Race: White
PROCEDURE(S):
CLINICAL DATA:
Right breast mass noted as 2.5 cm via diagnostic mammogram
Palpable nodes on exam not found with mammogram
Fish of Right breast mass and of 2 axillary nodes done concurrent
GROSS DESCRIPTION: Received in formalin is a single fragment of fat with tissue measuring
Right Axillary Nodes.
MICROSCOPIC DESCRIPTION: Microscopic examination shows infiltrating ductal carcinoma without direct invasion into the dermis.
HISTOLOGIC TYPE: Infiltrating Ductal Carcinoma
HISTOLOGIC GRADE: 2
GLANDULAR: 2
MITOTIC RATE: 2
NUCLEAR PLEOMORPHISM: 3
OVERALL GRADE: 2
PUBLISH
REPORT
RESULTS
Diagnostic Information
Biopsy
Finding
Anatomic site*
Entire right breast
Additional characteristics (anatomical relationship)
Histologic type
Infiltrating Ductal Carcinoma
Histologic grade
2
Length
Width
6
Height
Unit
mm
Single click
Margins involved?
No
Sentinel lymph nodes involved?
Lymph nodes involved
2
Lymph nodes examined
6
Biomarkers
Single click
Biomarker
Result
Measurement

FIG. 3

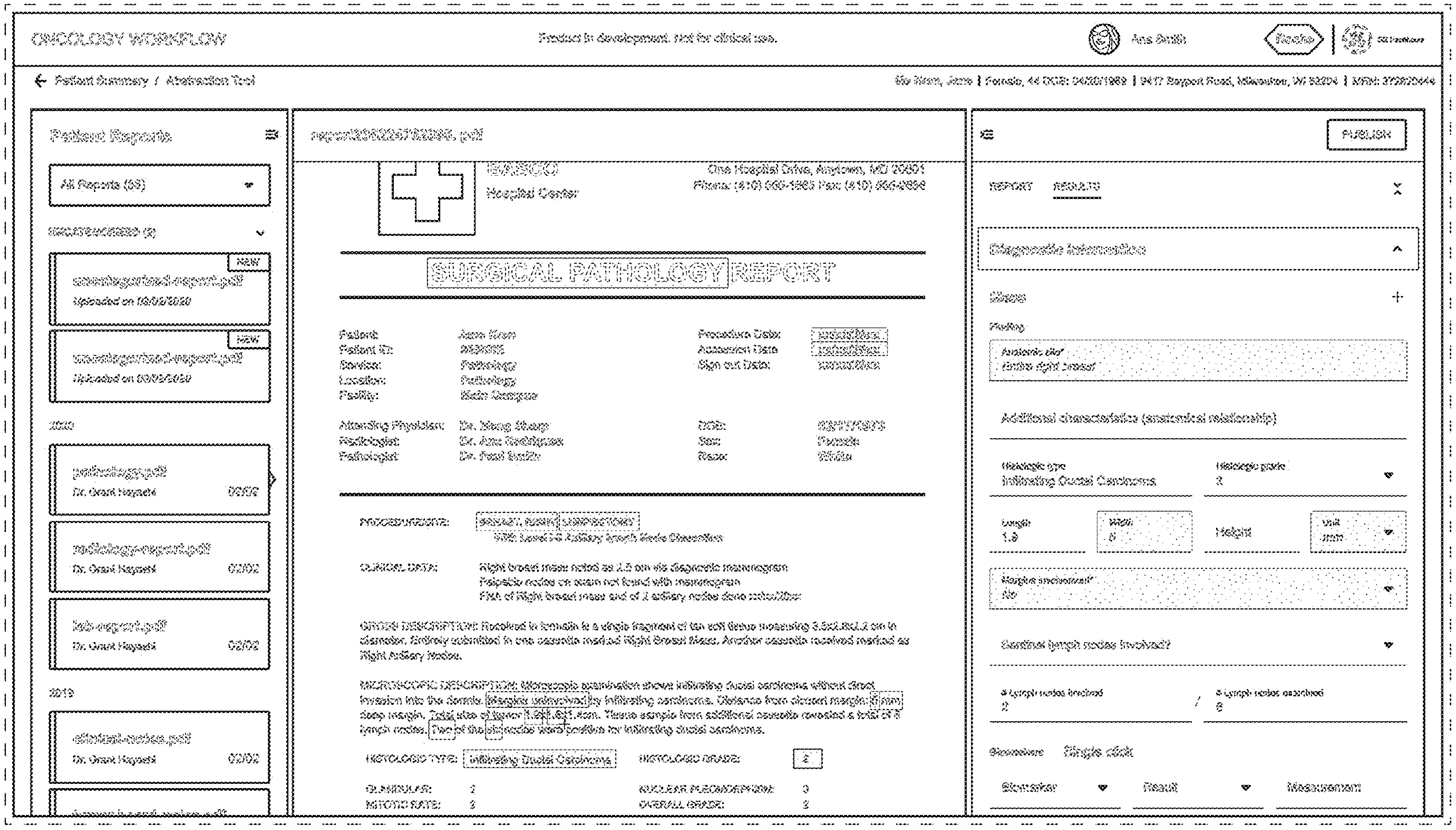
ONCOLOGY WORKFLOW
Product in development. Not for clinical use.
Ann Smith
Roche
Patient Summary / Abstraction Tool
Patient Reports
All Reports (53)
NEW
uncategorized-report.pdf
Uploaded on 10/03/2020
NEW
uncategorized-report.pdf
Uploaded on 10/03/2020
2020
pathology.pdf
Dr. Grant Hayashi 02/02
radiology-report.pdf
Dr. Grant Hayashi 02/02
lab-report.pdf
Dr. Grant Hayashi 02/02
2019
sentinel-nodes.pdf
Dr. Grant Hayashi 02/02
report20302257622884.pdf
BASCO
Hospital Center
SURGICAL PATHOLOGY REPORT
Patient:
Patient ID:
Service:
Location:
Facility:
Procedure Date:
Accession Date:
Sign out Date:
Attending Physician:
Radiologist:
Pathologist:
DOB:
Sex:
Race:
Female
White
PROCEDURE(S):
CLINICAL DATA:
GROSS DESCRIPTION:
MICROSCOPIC DESCRIPTION:
HISTOLOGIC TYPE:
Infiltrating Ductal Carcinoma
HISTOLOGIC GRADE:
TUBULES:
MITOTIC RATE:
NUCLEAR PLEOMORPHISM:
OVERALL GRADE:
PUBLISH
REPORT
RESULTS
Diagnostic Information
Blocks
Finding
Anatomic site
Entire right breast
Additional characteristics (anatomical relationship)
Histologic type
Infiltrating Ductal Carcinoma
Histologic grade
2
Length
1.9
Width
6
Height
Unit
mm
Margins involved?
No
Sentinel lymph nodes involved?
Lymph nodes involved
2
Lymph nodes examined
6
Biomarkers
Single click
Biomarker
Result
Measurement

FIG. 4

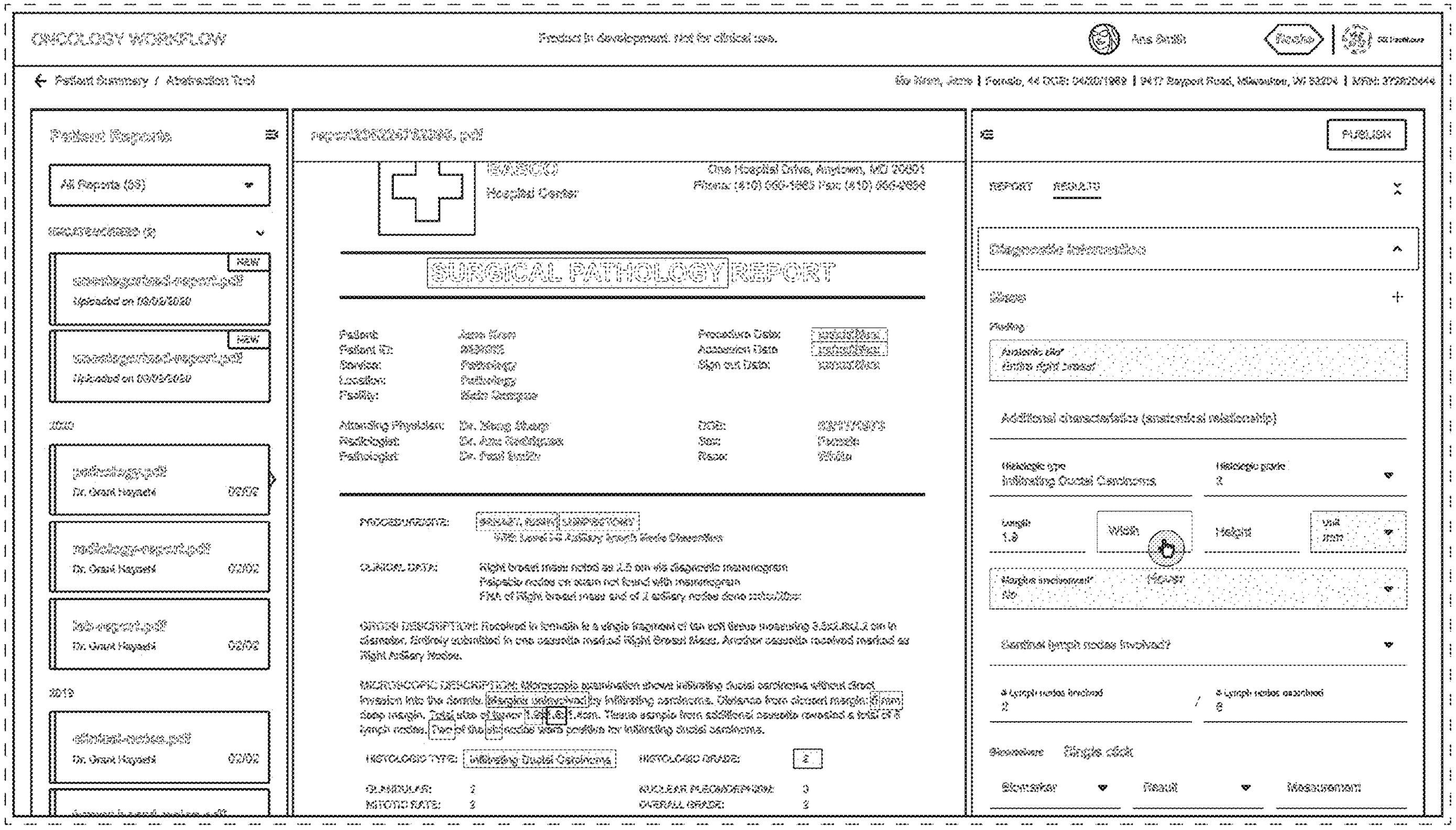
ONCOLOGY WORKFLOW
Product in development. Not for clinical use.
Ana Smith
Roche
Patient Summary / Abstraction Tool
Patient Reports
All Reports (53)
NEW
uncategorized-report.pdf
Uploaded on 10/03/2020
NEW
uncategorized-report.pdf
Uploaded on 10/03/2020
2020
pathology.pdf
Dr. Grant Hayashi 02/02
radiology-report.pdf
Dr. Grant Hayashi 02/02
lab-report.pdf
Dr. Grant Hayashi 02/02
2019
sentinel-nodes.pdf
Dr. Grant Hayashi 02/02
report20302257622884.pdf
BASCO
Hospital Center
SURGICAL PATHOLOGY REPORT
PUBLISH
REPORT
RESULTS
Diagnostic Information
Slides
Additional characteristics (anatomical relationship)
Histologic type
Infiltrating Ductal Carcinoma
Histologic grade
Length
Width
Height
Sentinel lymph nodes involved?
Biomarkers
Single click
Biomarker
Result
Measurement

FIG. 5

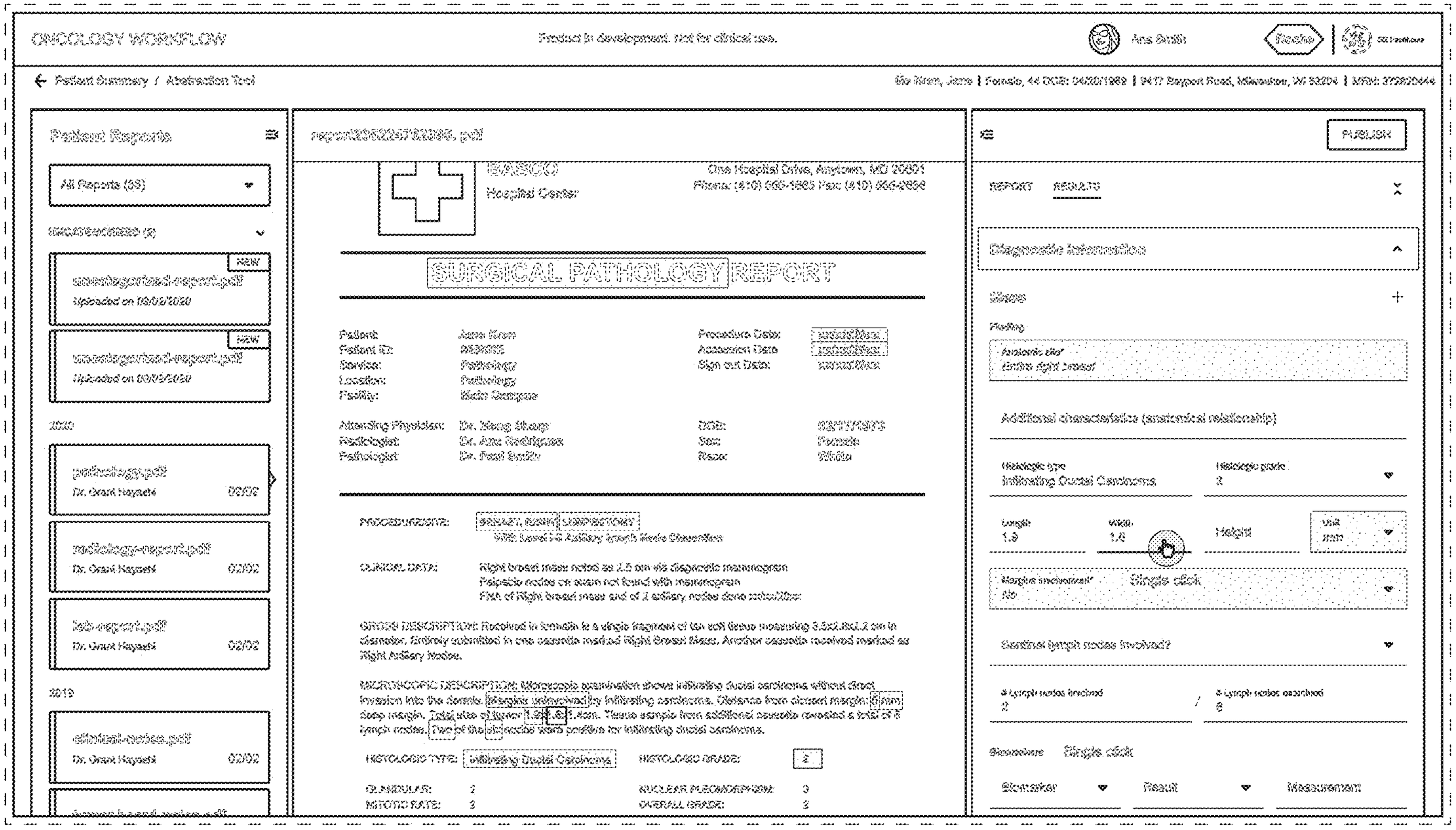
ONCOLOGY WORKFLOW
Product in development. Not for clinical use.
Ana Smith
Roche
Patient Summary / Abstraction Tool
Patient Reports
All Reports (53)
NEW
Uploaded on 10/02/2020
2020
pathology.pdf
Dr. Grant Hayashi 02/02
radiology-report.pdf
Dr. Grant Hayashi 02/02
lab-report.pdf
Dr. Grant Hayashi 02/02
2019
sentinel-nodes.pdf
Dr. Grant Hayashi 02/02
report20522257622864.pdf
BASCO
Hospital Center
One Hospital Drive, Anytown, MD 20601
SURGICAL PATHOLOGY REPORT
Patient: Jane Kron
Patient ID: 8829385
Service: Pathology
Location: Pathology
Facility: Main Campus
Procedure Date:
Accession Date:
Sign out Date:
Attending Physician: Dr. Meng Sharp
Radiologist: Dr. Ana Rodriguez
Pathologist: Dr. Paul Smith
DOB:
Sex: Female
Race: White
PROCEDURE(S):
CLINICAL DATA:
GROSS DESCRIPTION:
MICROSCOPIC DESCRIPTION:
HISTOLOGIC TYPE: Infiltrating Ductal Carcinoma
HISTOLOGIC GRADE: 2
TUBULES: 2
MITOTIC RATE: 2
NUCLEAR PLEOMORPHISM: 3
OVERALL GRADE: 2
PUBLISH
REPORT
RESULTS
Diagnostic Information
Blocks
Finding
Anatomic site
Entire right breast
Additional characteristics (anatomical relationship)
Histologic type
Infiltrating Ductal Carcinoma
Histologic grade
2
Length
1.9
Width
1.6
Height
Unit
mm
Margins involvement
No
Single click
Sentinel lymph nodes involved?
Lymph nodes involved
2
Lymph nodes examined
6
Biomarkers
Single click
Biomarker
Result
Measurement

FIG. 6

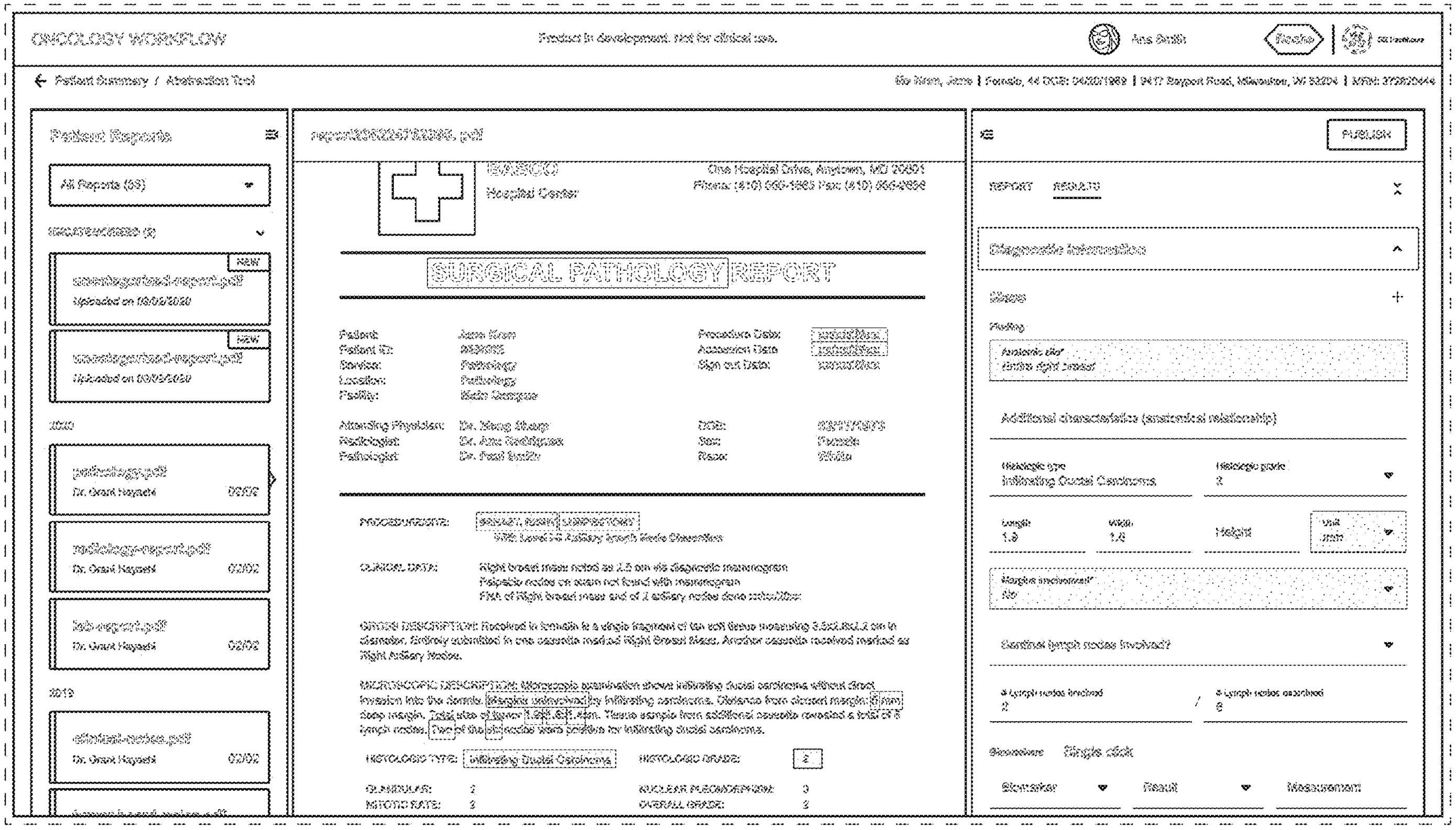
ONCOLOGY WORKFLOW
Product in development. Not for clinical use.
Ana Smith
Roche
Patient Summary / Abstraction Tool
Patient Reports
All Reports (53)
NEW
Uploaded on 10/02/2020
2020
pathology.pdf
Dr. Grant Hayashi 02/02
radiology-report.pdf
Dr. Grant Hayashi 02/02
lab-report.pdf
Dr. Grant Hayashi 02/02
2019
sentinel-nodes.pdf
Dr. Grant Hayashi 02/02
report20202257622884.pdf
BASCO
Hospital Center
One Hospital Drive, Anytown, MD 20601
SURGICAL PATHOLOGY REPORT
Patient: Jane Kron
Patient ID:
Service: Pathology
Location: Pathology
Facility: Main Campus
Procedure Date:
Accession Date
Sign out Date:
Attending Physician: Dr. Meng Sharp
Radiologist: Dr. Ana Rodriguez
Pathologist: Dr. Paul Smith
DOB:
Sex: Female
Race: White
PROCEDURE(S):
CLINICAL DATA:
Right breast mass noted as 2.5 cm via diagnostic mammogram
Palpable nodes on exam not found with mammogram
Fish of Right breast mass and of 2 axillary nodes done concurrent
GROSS DESCRIPTION: Received in formalin is a single fragment of fat with tissue measuring
diameter. Entirely submitted in one cassette marked Right Breast Mass. Another cassette received marked as
Right Axillary Nodes.
MICROSCOPIC DESCRIPTION: Microscopic examination shows infiltrating ductal carcinoma without direct
invasion into the dermis. Margins uninvolved by infiltrating carcinoma. Distance from closest margin:
deep margin. Total size of tumor
lymph nodes. Two of the six nodes were positive for infiltrating ductal carcinoma.
HISTOLOGIC TYPE: Infiltrating Ductal Carcinoma
HISTOLOGIC GRADE: 2
GLANDULAR: 2
MITOTIC RATE: 2
NUCLEAR PLEOMORPHISM: 3
OVERALL GRADE: 2
PUBLISH
REPORT
RESULTS
Diagnostic Information
Biopsy
Finding
Anatomic site*
Entire right breast
Additional characteristics (anatomical relationship)
Histologic type
Infiltrating Ductal Carcinoma
Histologic grade
2
Length
1.9
Width
1.6
Height
Unit
mm
Margins involved?*
No
Sentinel lymph nodes involved?
Lymph nodes involved
2
Lymph nodes examined
6
Biomarkers
Single click
Biomarker
Result
Measurement

FIG. 7

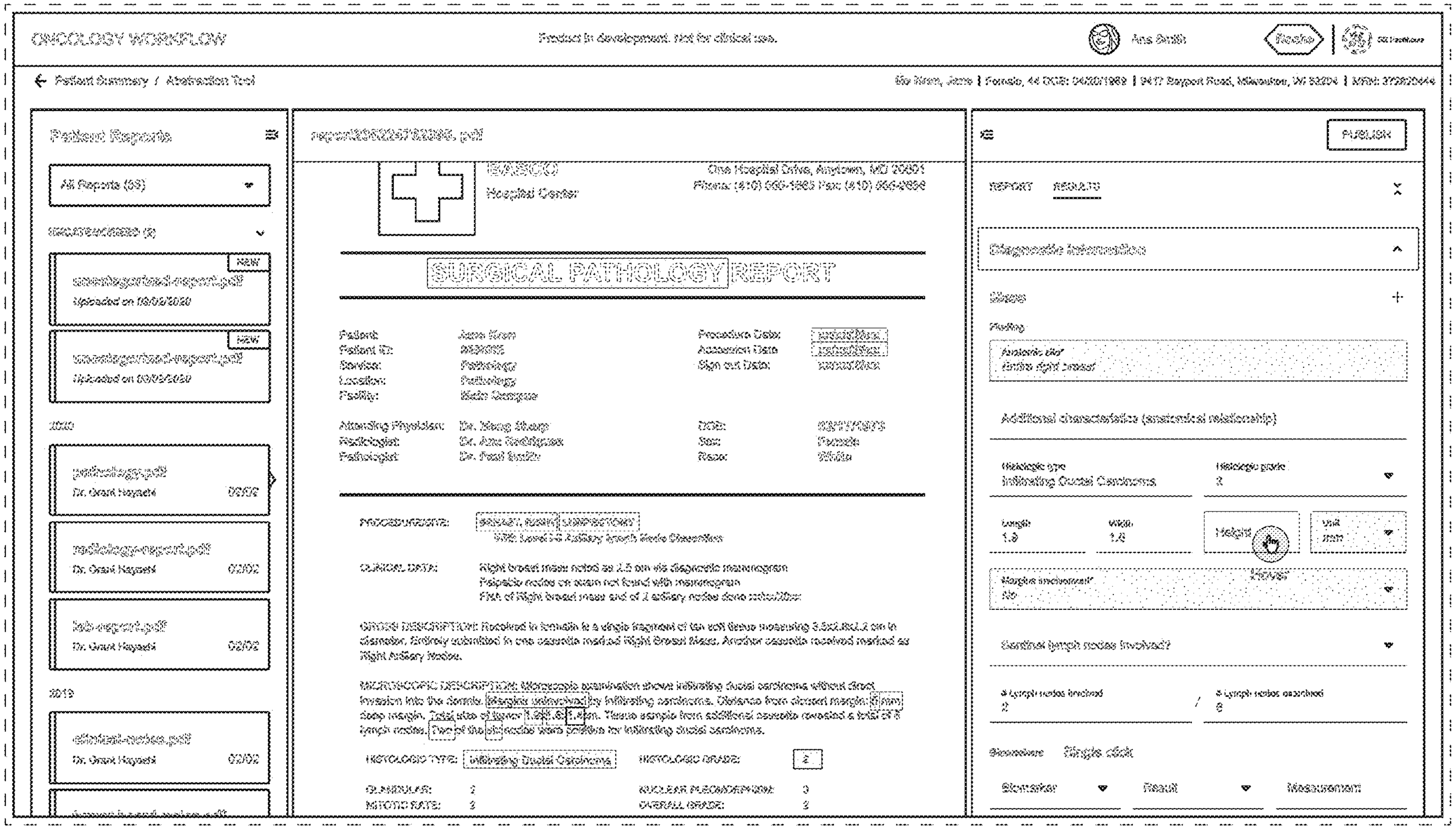
ONCOLOGY WORKFLOW
Product in development. Not for clinical use.
Ana Smith
Patient Summary / Abstraction Tool
Patient Reports
All Reports (53)
NEW
Uploaded on 10/02/2020
2020
pathology.pdf
Dr. Grant Hayashi 02/02
radiology-report.pdf
Dr. Grant Hayashi 02/02
lab-report.pdf
Dr. Grant Hayashi 02/02
2019
sentinel-nodes.pdf
Dr. Grant Hayashi 02/02
report20202257622884.pdf
BASCO
Hospital Center
SURGICAL PATHOLOGY REPORT
Patient:
Patient ID:
Service:
Location:
Facility:
Procedure Date:
Accession Date:
Sign out Date:
Attending Physician:
Radiologist:
Pathologist:
DOB:
Sex:
Race:
PROCEDURE(S):
CLINICAL DATA:
GROSS DESCRIPTION:
MICROSCOPIC DESCRIPTION:
HISTOLOGIC TYPE:
Infiltrating Ductal Carcinoma
HISTOLOGIC GRADE:
TUBULES:
MITOTIC RATE:
NUCLEAR PLEOMORPHISM:
OVERALL GRADE:
PUBLISH
REPORT
RESULTS
Diagnostic Information
Biopsy
Finding
Anatomic site
Entire right breast
Additional characteristics (anatomical relationship)
Histologic type
Infiltrating Ductal Carcinoma
Histologic grade
Length
Width
Height
Unit
mm
Margins involved?
No
Sentinel lymph nodes involved?
Lymph nodes involved
Lymph nodes examined
Biomarkers
Single click
Biomarker
Result
Measurement

FIG. 8

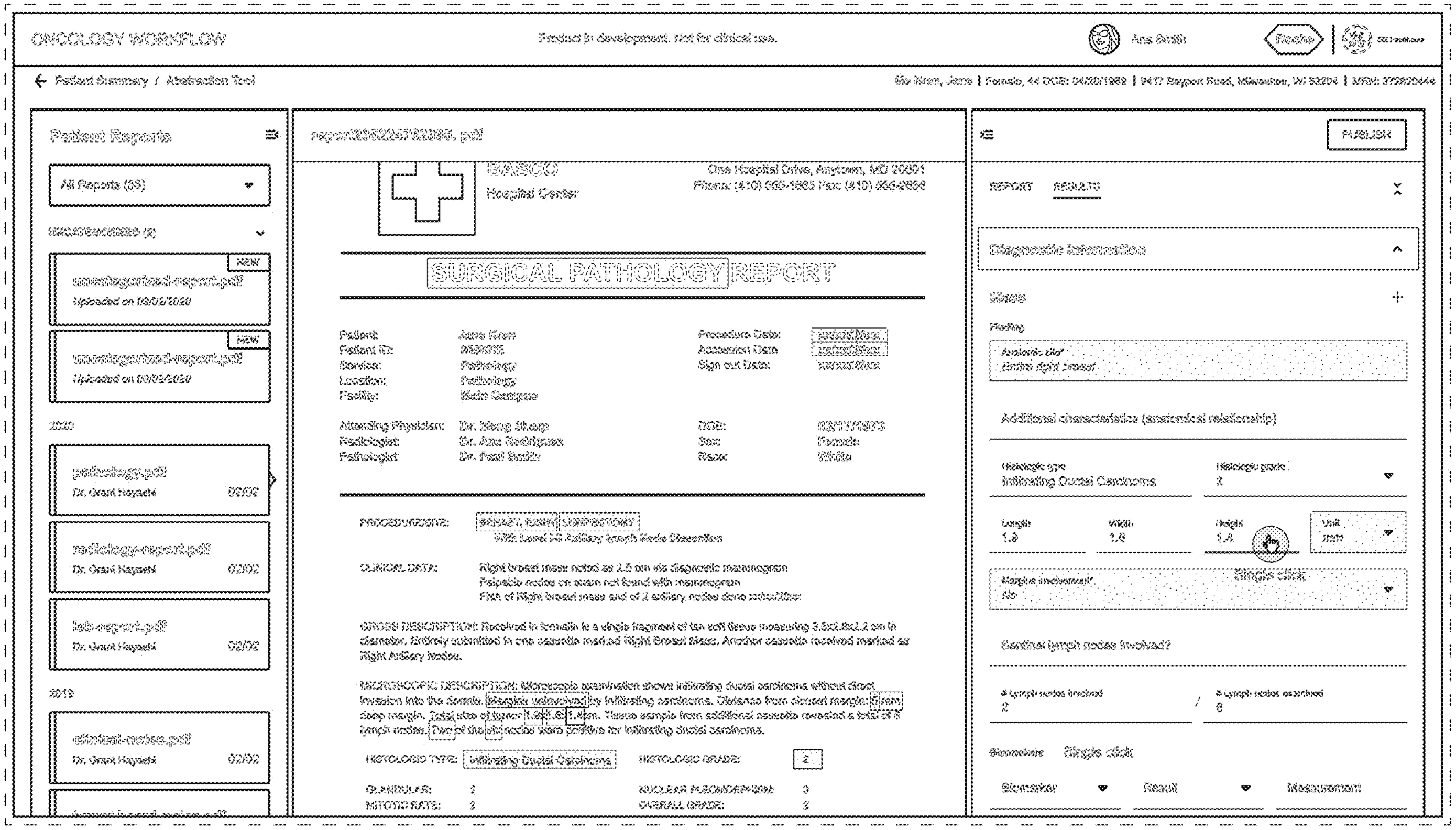
ONCOLOGY WORKFLOW
Product in development. Not for clinical use.
Ana Smith
Roche
Patient Summary / Abstraction Tool
Patient Reports
All Reports (53)
NEW
uncategorized-report.pdf
Uploaded on 10/03/2020
NEW
uncategorized-report.pdf
Uploaded on 10/03/2020
2020
pathology.pdf
Dr. Grant Hayashi 02/02
radiology-report.pdf
Dr. Grant Hayashi 02/02
lab-report.pdf
Dr. Grant Hayashi 02/02
2019
sentinel-nodes.pdf
Dr. Grant Hayashi 02/02
report20522257622864.pdf
BASCO
Hospital Center
One Hospital Drive, Anytown, MD 20601
SURGICAL PATHOLOGY REPORT
Patient: Jane Kron
Patient ID: 8829385
Service: Pathology
Location: Pathology
Facility: Main Campus
Procedure Date:
Accession Date:
Sign out Date:
Attending Physician: Dr. Meng Sharp
Radiologist: Dr. Ana Rodriguez
Pathologist: Dr. Paul Smith
DOB:
Sex: Female
Race: White
PROCEDURE(S):
CLINICAL DATA:
GROSS DESCRIPTION:
MICROSCOPIC DESCRIPTION:
HISTOLOGIC TYPE: Infiltrating Ductal Carcinoma
HISTOLOGIC GRADE: 2
TUBULES:
MITOTIC RATE:
NUCLEAR PLEOMORPHISM:
OVERALL GRADE:
PUBLISH
REPORT
RESULTS
Diagnostic Information
Blocks
Finding
Anatomic site*
Breast, right, breast
Additional characteristics (anatomical relationship)
Histologic type
Infiltrating Ductal Carcinoma
Histologic grade
2
Length
1.9
Width
1.6
Height
1.4
Unit
mm
Margins involvement*
No
Single click
Sentinel lymph nodes involved?
Lymph nodes involved
2
Lymph nodes examined
6
Biomarkers
Single click
Biomarker
Result
Measurement

FIG. 9

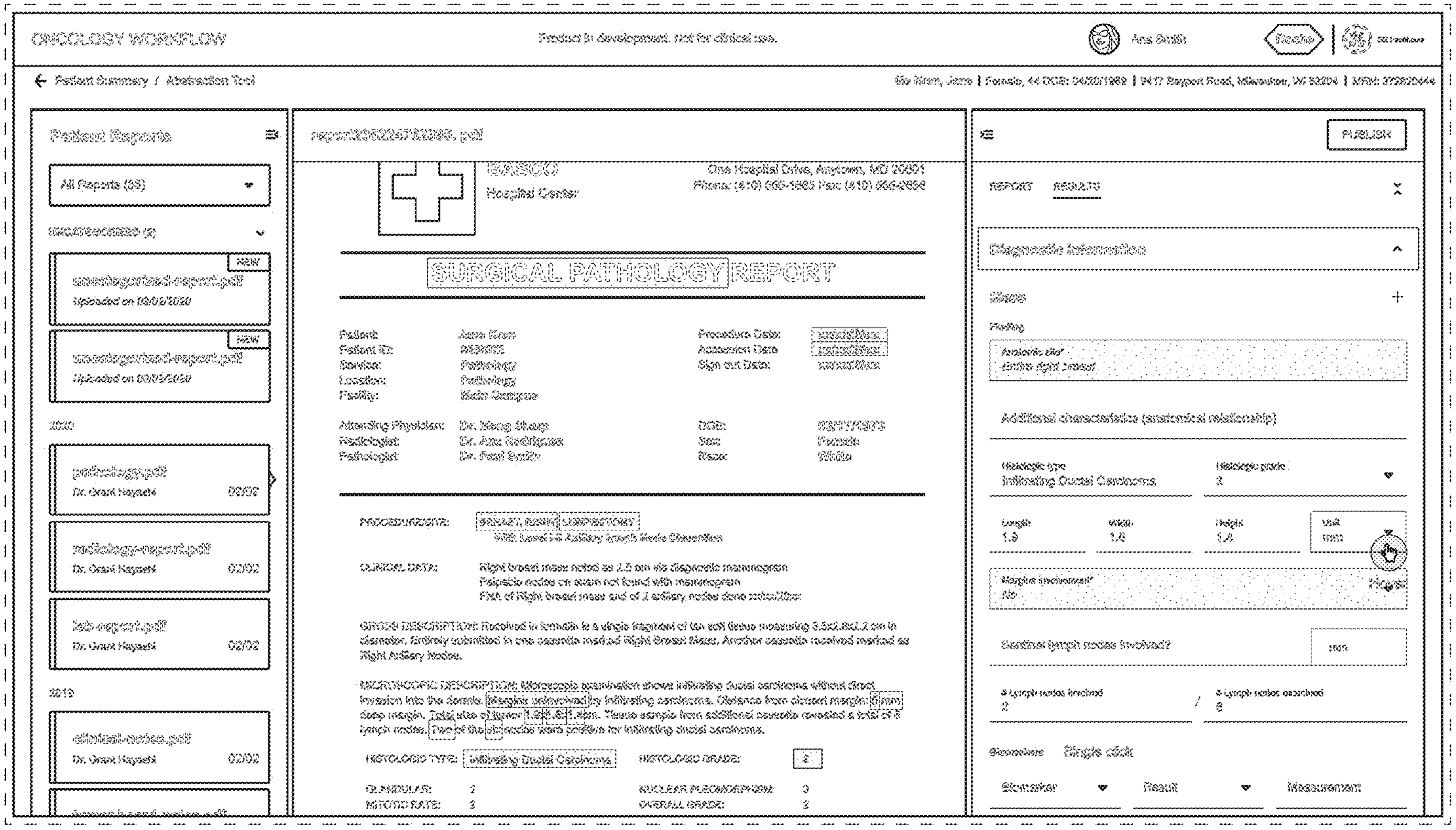
ONCOLOGY WORKFLOW
Product in development. Not for clinical use.
Ana Smith
Roche
Patient Summary / Abstraction Tool
Patient Reports
All Reports (53)
NEW
uncategorized-report.pdf
Uploaded on 10/03/2020
NEW
uncategorized-report.pdf
Uploaded on 10/03/2020
2020
pathology.pdf
Dr. Grant Hayashi 02/02
radiology-report.pdf
Dr. Grant Hayashi 02/02
lab-report.pdf
Dr. Grant Hayashi 02/02
2019
sentinel-nodes.pdf
Dr. Grant Hayashi 02/02
report20522257622864.pdf
BASCO
Hospital Center
SURGICAL PATHOLOGY REPORT
Patient:
Patient ID:
Service:
Location:
Facility:
Procedure Date:
Accession Date
Sign out Date:
Attending Physician:
Radiologist:
Pathologist:
DOB:
Sex:
Race:
Female
White
PROCEDURE(S):
CLINICAL DATA:
GROSS DESCRIPTION:
MICROSCOPIC DESCRIPTION:
HISTOLOGIC TYPE:
Infiltrating Ductal Carcinoma
HISTOLOGIC GRADE:
GLANDULAR:
MITOTIC RATE:
NUCLEAR PLEOMORPHISM:
OVERALL GRADE:
PUBLISH
REPORT
RESULTS
Diagnostic Information
Blocks
Finding
Anatomic site*
Entire right breast
Additional characteristics (anatomical relationship)
Histologic type
Infiltrating Ductal Carcinoma
Histologic grade
2
Length
1.9
Width
1.6
Height
1.4
Unit
mm
Margins involved?
No
Sentinel lymph nodes involved?
Lymph nodes involved
2
Lymph nodes examined
6
Biomarkers
Single click
Biomarker
Result
Measurement

FIG. 10

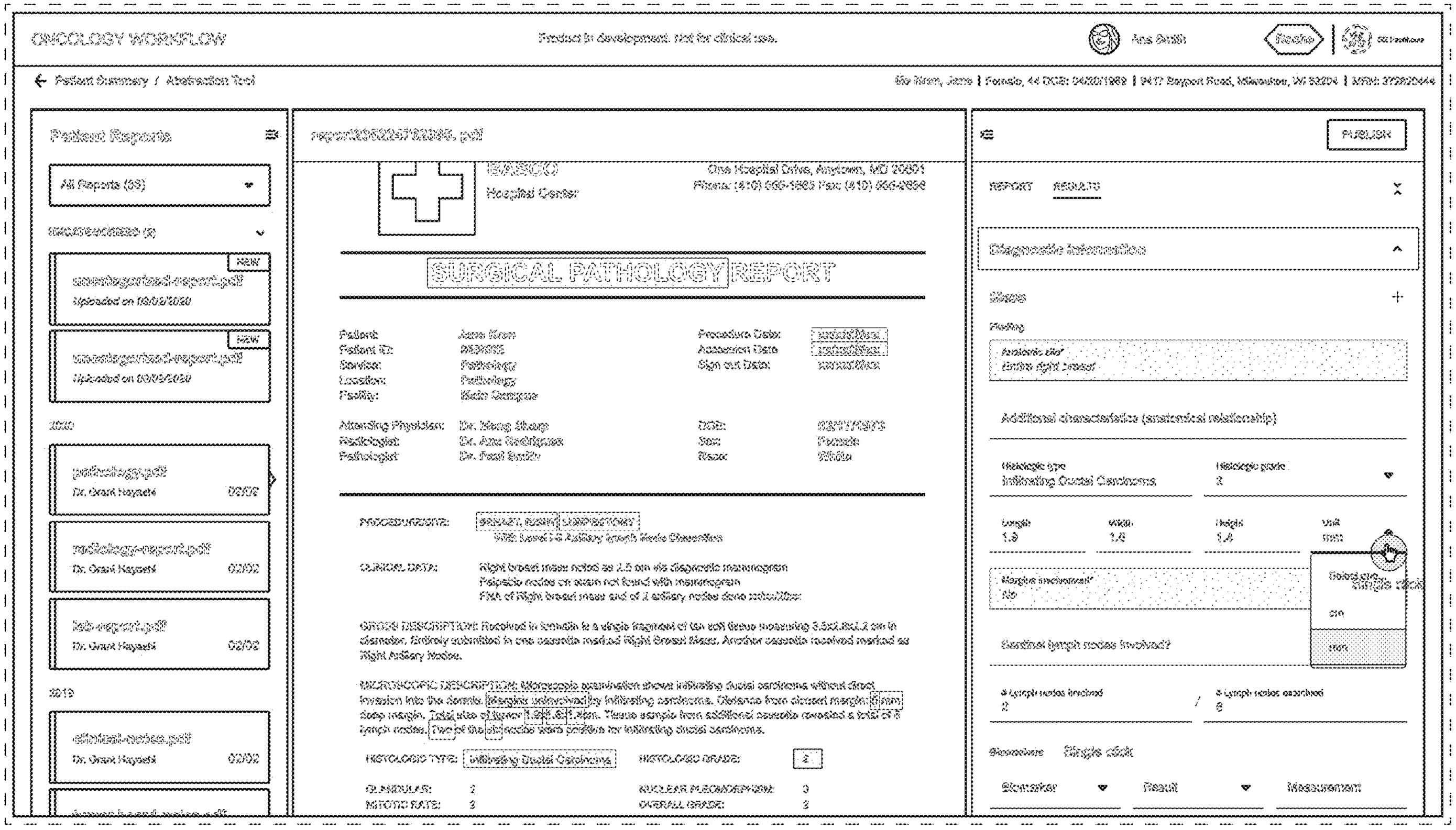
ONCOLOGY WORKFLOW
Product in development. Not for clinical use.
Ana Smith
Patient Summary / Abstraction Tool
Patient Reports
All Reports (53)
NEW
uncategorized-report.pdf
Uploaded on 10/03/2020
NEW
uncategorized-report.pdf
Uploaded on 10/03/2020
2020
pathology.pdf
Dr. Grant Hayashi 02/02
radiology-report.pdf
Dr. Grant Hayashi 02/02
lab-report.pdf
Dr. Grant Hayashi 02/02
2019
sentinel-nodes.pdf
Dr. Grant Hayashi 02/02
report20522257622864.pdf
BASCO
Hospital Center
One Hospital Drive, Anytown, MD 20601
SURGICAL PATHOLOGY REPORT
Patient: Jane Kron
Patient ID:
Service: Pathology
Location: Pathology
Facility: Main Campus
Procedure Date:
Accession Date:
Sign out Date:
Attending Physician: Dr. Meng Sharp
Radiologist: Dr. Ana Rodriguez
Pathologist: Dr. Paul Smith
DOB:
Sex: Female
Race: White
PROCEDURE(S):
CLINICAL DATA:
GROSS DESCRIPTION:
MICROSCOPIC DESCRIPTION:
HISTOLOGIC TYPE: Infiltrating Ductal Carcinoma
HISTOLOGIC GRADE:
TUBULES:
MITOTIC RATE:
NUCLEAR PLEOMORPHISM:
OVERALL GRADE:
PUBLISH
REPORT
RESULTS
Diagnostic Information
Blocks
Finding
Anatomic site*
Entire right breast
Additional characteristics (anatomical relationship)
Histologic type
Infiltrating Ductal Carcinoma
Histologic grade
2
Length
1.9
Width
1.6
Height
1.4
Unit
mm
Margins involved?*
No
Sentinel lymph nodes involved?
Lymph nodes involved
2
Lymph nodes examined
6
Biomarkers
Single click
Biomarker
Result
Measurement

FIG. 11

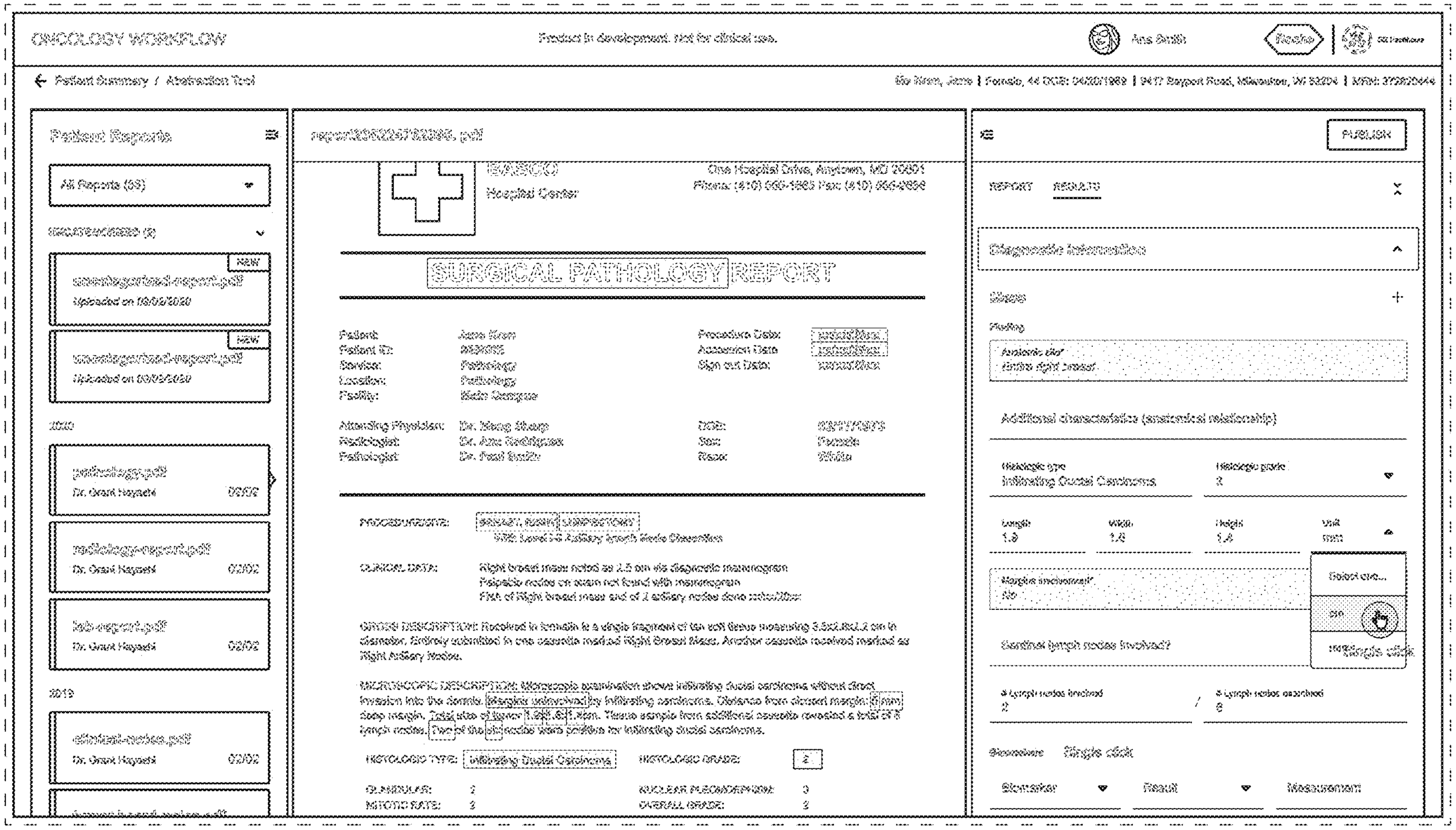
ONCOLOGY WORKFLOW
Product in development. Not for clinical use.
Ana Smith
Roche
Patient Summary / Abstraction Tool
Patient Reports
All Reports (53)
NEW
uncategorized-report.pdf
Uploaded on 10/03/2020
NEW
uncategorized-report.pdf
Uploaded on 10/03/2020
2020
pathology.pdf
Dr. Grant Hayashi 02/02
radiology-report.pdf
Dr. Grant Hayashi 02/02
lab-report.pdf
Dr. Grant Hayashi 02/02
2019
sentinel-nodes.pdf
Dr. Grant Hayashi 02/02
report20302257622894.pdf
BASCO
Hospital Center
One Hospital Drive, Anytown, MD 20801
SURGICAL PATHOLOGY REPORT
Patient: Jane Kron
Patient ID: 8829385
Service: Pathology
Location: Pathology
Facility: Main Campus
Procedure Date:
Accession Date:
Sign out Date:
Attending Physician: Dr. Meng Sharp
Radiologist: Dr. Ana Rodriguez
Pathologist: Dr. Paul Smith
DOB:
Sex: Female
Race: White
PROCEDURE(S):
CLINICAL DATA:
GROSS DESCRIPTION:
MICROSCOPIC DESCRIPTION:
HISTOLOGIC TYPE: Infiltrating Ductal Carcinoma
HISTOLOGIC GRADE:
TUBULES:
MITOTIC RATE:
NUCLEAR PLEOMORPHISM:
OVERALL GRADE:
PUBLISH
REPORT
RESULTS
Diagnostic Information
Blocks
Finding
Anatomic site*
Entire right breast
Additional characteristics (anatomical relationship)
Histologic type
Infiltrating Ductal Carcinoma
Histologic grade
2
Length
1.9
Width
1.6
Height
1.4
Unit
mm
Margins involved?*
No
Select one...
Sentinel lymph nodes involved?
Single click
Lymph nodes involved
2
Lymph nodes examined
6
Biomarkers
Single click
Biomarker
Result
Measurement

FIG. 12

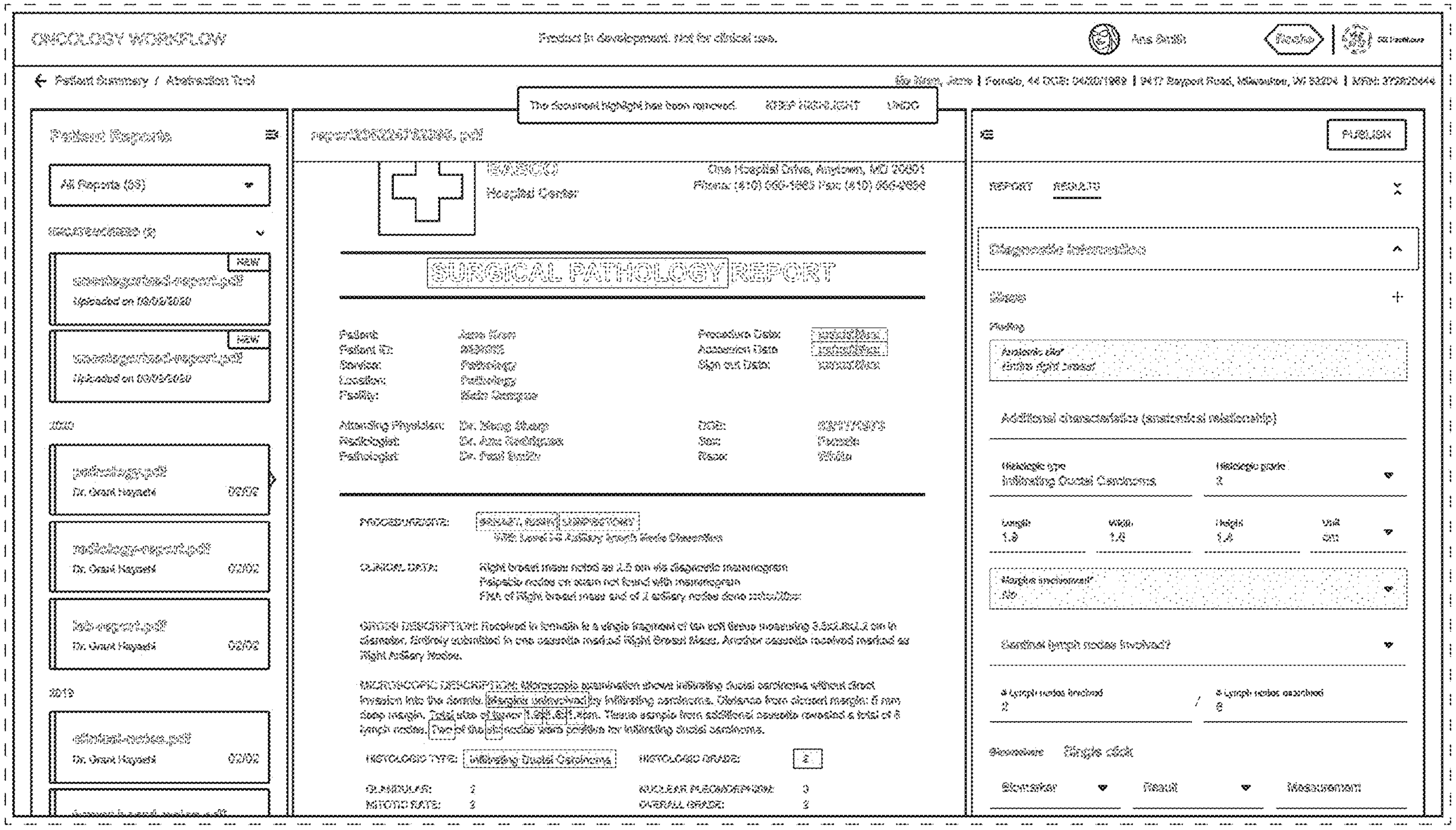
ONCOLOGY WORKFLOW
Product in development. Not for clinical use.
Patient Summary / Abstraction Tool
The document highlight has been removed.
KEEP HIGHLIGHT
UNDO
Patient Reports
All Reports (53)
NEW
uncategorized-report.pdf
Uploaded on 10/03/2020
NEW
uncategorized-report.pdf
Uploaded on 10/03/2020
2020
pathology.pdf
Dr. Grant Hayashi 02/02
radiology-report.pdf
Dr. Grant Hayashi 02/02
lab-report.pdf
Dr. Grant Hayashi 02/02
2019
sentinel-nodes.pdf
Dr. Grant Hayashi 02/02
report20522257622864.pdf
BASCO
Hospital Center
One Hospital Drive, Anytown, MD 20601
SURGICAL PATHOLOGY REPORT
Patient: Jane Krom
Patient ID: 8829385
Service: Pathology
Location: Pathology
Facility: Main Campus
Procedure Date:
Accession Date:
Sign out Date:
Attending Physician: Dr. Meng Sharp
Radiologist: Dr. Ana Rodriguez
Pathologist: Dr. Paul Smith
DOB:
Sex: Female
Race: White
PROCEDURE(S):
CLINICAL DATA:
Right breast mass noted as 2.5 cm via diagnostic mammogram
Palpable nodes on exam not found with mammogram
Fish of Right breast mass and of 2 axillary nodes done concurrent
GROSS DESCRIPTION: Received in formalin is a single fragment of fat with tissue measuring 3.5x2.8x1.2 cm in diameter. Entirely submitted in one cassette marked Right Breast Mass. Another cassette received marked as Right Axillary Nodes.
MICROSCOPIC DESCRIPTION: Microscopic examination shows infiltrating ductal carcinoma without direct invasion into the dermis. Margins uninvolved by infiltrating carcinoma. Distance from closest margin: 8 mm deep margin. Total size of tumor 1.2x1.6x1.4cm. Tissue sample from additional cassette revealed a total of 8 lymph nodes. Two of the six nodes were positive for infiltrating ductal carcinoma.
HISTOLOGIC TYPE: Infiltrating Ductal Carcinoma
HISTOLOGIC GRADE: 2
GLANDULAR: 2
MITOTIC RATE: 2
NUCLEAR PLEOMORPHISM: 3
OVERALL GRADE: 2
PUBLISH
REPORT
REGULTS
Diagnostic Information
Biopsy
Finding
Anatomic site
Entire right breast
Additional characteristics (anatomical relationship)
Histologic type
Infiltrating Ductal Carcinoma
Histologic grade
2
Length
1.2
Width
1.6
Height
1.4
Unit
cm
Margins involved?
No
Sentinel lymph nodes involved?
Lymph nodes involved
2
Lymph nodes examined
8
Biomarkers
Single click
Biomarker
Result
Measurement

FIG. 13

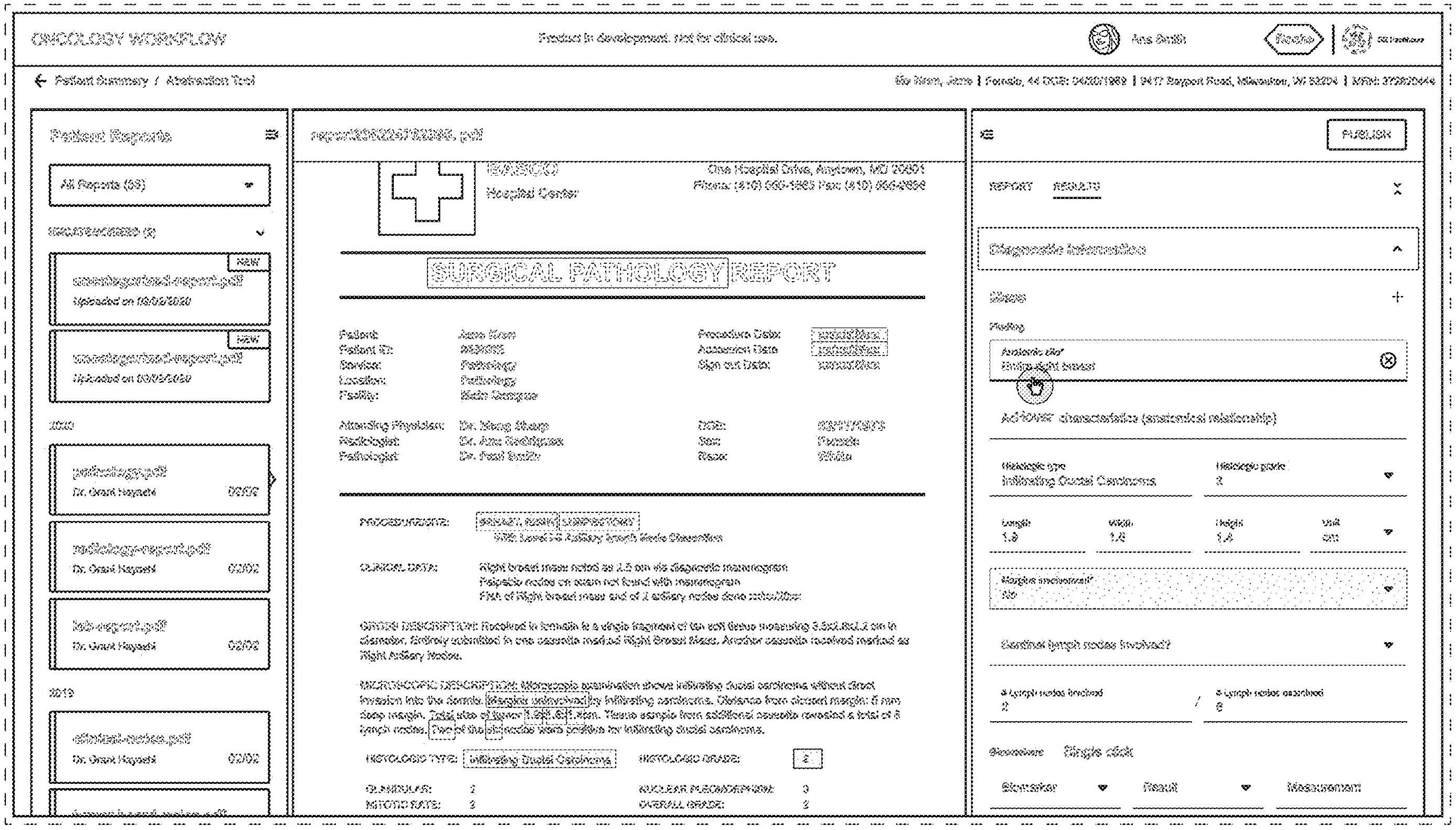
ONCOLOGY WORKFLOW
Product in development. Not for clinical use.
Ana Smith
Roche
Patient Summary / Abstraction Tool
Patient Reports
All Reports (53)
NEW
Uploaded on 10/02/2020
2020
pathology.pdf
Dr. Grant Hayashi 02/02
radiology-report.pdf
Dr. Grant Hayashi 02/02
lab-report.pdf
Dr. Grant Hayashi 02/02
2019
sentinel-nodes.pdf
Dr. Grant Hayashi 02/02
report20022257622884.pdf
BASCO
Hospital Center
One Hospital Drive, Anytown, MD 20801
SURGICAL PATHOLOGY REPORT
Patient: Jane Kron
Patient ID: 8829385
Service: Pathology
Location: Pathology
Facility: Main Campus
Procedure Date:
Accession Date:
Sign out Date:
Attending Physician: Dr. Meng Sharp
Radiologist: Dr. Ana Rodriguez
Pathologist: Dr. Paul Smith
DOB:
Sex: Female
Race: White
PROCEDURE(S):
CLINICAL DATA:
GROSS DESCRIPTION:
MICROSCOPIC DESCRIPTION:
HISTOLOGIC TYPE: Infiltrating Ductal Carcinoma
HISTOLOGIC GRADE: 2
TUBULES: 2
MITOTIC RATE: 2
NUCLEAR PLEOMORPHISM: 3
OVERALL GRADE: 2
PUBLISH
REPORT
RESULTS
Diagnostic Information
Biopsy
Finding
Anatomic site*
Entire right breast
Add/Edit characteristics (anatomical relationship)
Histologic type
Infiltrating Ductal Carcinoma
Histologic grade
2
Length
1.9
Width
1.6
Height
1.4
Unit
cm
Margins involved?*
No
Sentinel lymph nodes involved?
Lymph nodes involved
2
Lymph nodes examined
6
Biomarkers
Single click
Biomarker
Result
Measurement

FIG. 14

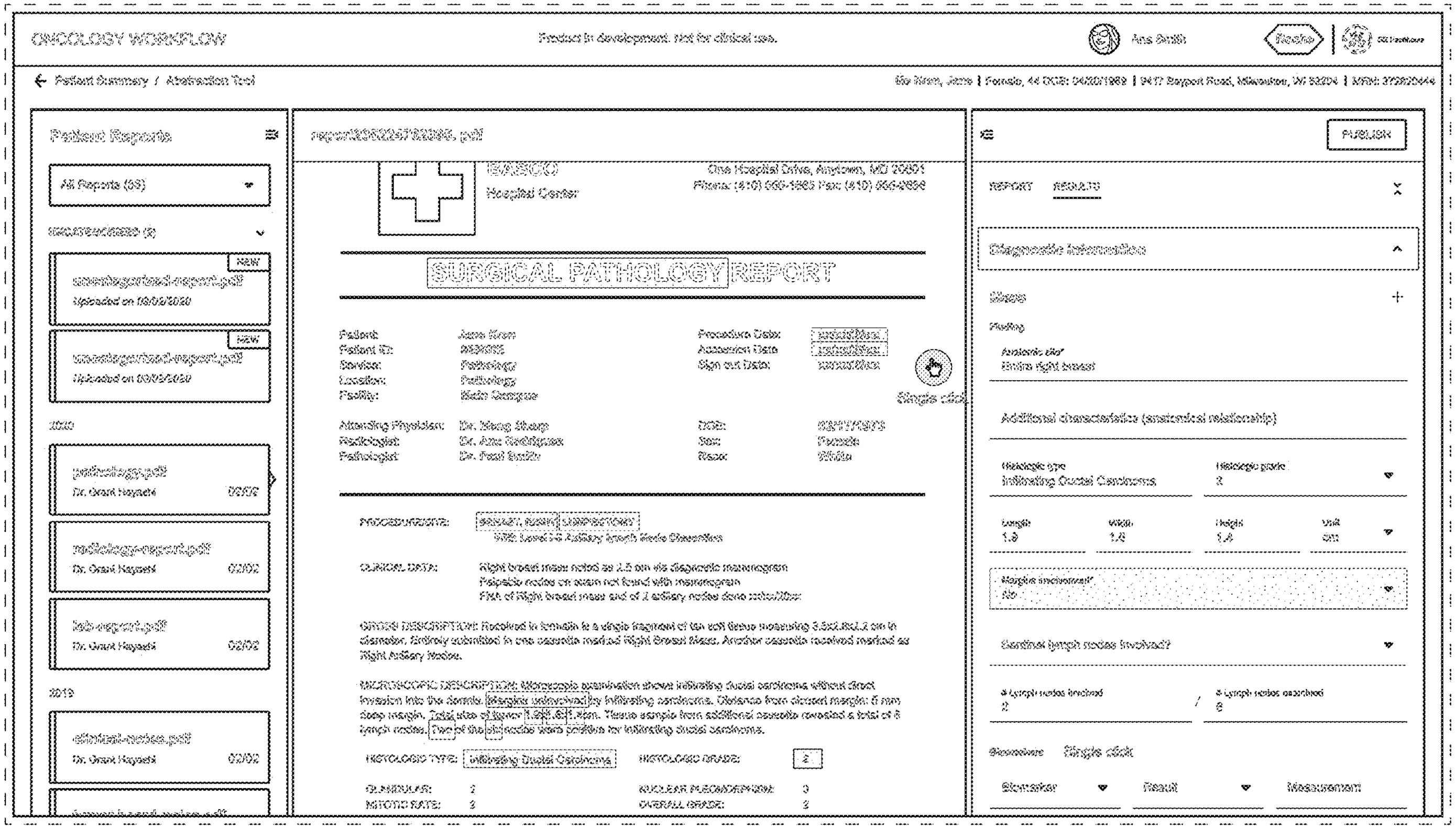
ONCOLOGY WORKFLOW
Product in development. Not for clinical use.
Ana Smith
Roche
Patient Summary / Abstraction Tool
Patient Reports
All Reports (53)
NEW
uncategorized-report.pdf
Uploaded on 10/03/2020
NEW
uncategorized-report.pdf
Uploaded on 10/03/2020
2020
pathology.pdf
Dr. Grant Hayashi 02/02
radiology-report.pdf
Dr. Grant Hayashi 02/02
lab-report.pdf
Dr. Grant Hayashi 02/02
2019
sentinel-nodes.pdf
Dr. Grant Hayashi 02/02
report20522257622864.pdf
BASCO
Hospital Center
One Hospital Drive, Anytown, MD 20601
SURGICAL PATHOLOGY REPORT
Patient: Jane Kron
Patient ID: 8829385
Service: Pathology
Location: Pathology
Facility: Main Campus
Procedure Date:
Accession Date
Sign out Date:
Single click
Attending Physician: Dr. Meng Sharp
Radiologist: Dr. Ana Rodriguez
Pathologist: Dr. Paul Smith
DOB:
Sex: Female
Race: White
PROCEDURE(S):
CLINICAL DATA:
Right breast mass noted as 2.5 cm via diagnostic mammogram
Palpable nodes on exam not found with mammogram
Fish of Right breast mass and of 2 axillary nodes done concurrent
GROSS DESCRIPTION: Received in formalin is a single fragment of fat with tissue measuring
Right Axillary Nodes.
MICROSCOPIC DESCRIPTION: Microscopic examination shows infiltrating ductal carcinoma without direct
invasion into the dermis. Margins uninvolved by infiltrating carcinoma. Distance from closest margin:
deep margin. Total size of tumor
Tissue sample from additional cassette revealed a total of 6
lymph nodes. Two of the six nodes were positive for infiltrating ductal carcinoma.
HISTOLOGIC TYPE: Infiltrating Ductal Carcinoma
HISTOLOGIC GRADE: 2
GLANDULAR:
MITOTIC RATE:
NUCLEAR PLEOMORPHISM:
OVERALL GRADE:
PUBLISH
REPORT
RESULTS
Diagnostic Information
Biopsy
Finding
Anatomic site
Entire right breast
Additional characteristics (anatomical relationship)
Histologic type
Infiltrating Ductal Carcinoma
Histologic grade
2
Length
1.9
Width
1.6
Height
1.4
Unit
cm
Margins involved?
No
Sentinel lymph nodes involved?
Lymph nodes involved
2
Lymph nodes examined
6
Biomarkers
Single click
Biomarker
Result
Measurement

FIG. 15