US00D974393S

(12) United States Design Patent

Barnard et al.

(10) Patent No.: US D974,393 S
(45) Date of Patent: ** Jan. 3, 2023

(54) **DISPLAY SCREEN OR PORTION THEREOF WITH GRAPHICAL USER INTERFACE FOR SELECTING TEXT WITH AN ABSTRACTION TOOL**

(71) Applicant: **Roche Molecular Systems, Inc.**, Pleasanton, CA (US)

(72) Inventors: **Cindy K. Barnard**, Santa Clara, CA (US); **Sambasivarao Byrapuneni**, Pleasanton, CA (US); **Diwakar Chapagain**, Cupertino, CA (US); **Archana P. Dorge**, Campbell, CA (US); **Catherine M. Jeu**, San Jose, CA (US); **Rengaraja Kesavan**, Pleasanton, CA (US); **Kaushal D. Parekh**, Redwood City, CA (US); **Raman Ramanathan**, San Jose, CA (US); **David M. Schlossman**, Columbia, MO (US); **Vishakha Sharma**, Foster City, CA (US)

(73) Assignee: **Roche Molecular Systems, Inc.**, Pleasanton, CA (US)

(**) Term: **15 Years**

(21) Appl. No.: **29/766,583**

(22) Filed: **Jan. 15, 2021**

(51) **LOC (14) Cl.** **14-04**

(52) **U.S. Cl.**
USPC **D14/486**

(58) **Field of Classification Search**
USPC D14/485–495
CPC G06F 3/048; G06F 3/0481; G06F 3/04817; G06F 3/0482; G06F 3/0483; G06F 3/04842; G06F 3/0485; G06F 3/04855; G06F 3/0486; G06F 3/0488; G06F 3/04886; G06F 9/451; G06F 40/103; G06F 40/106; G06F 40/189; G06F 40/191
See application file for complete search history.

(56) **References Cited**

U.S. PATENT DOCUMENTS

D733,176 S * 6/2015 Lin D14/486
D809,530 S * 2/2018 Matheson D14/485
D836,652 S * 12/2018 Fowler D14/486
D841,031 S * 2/2019 Orlando D14/486
(Continued)

Primary Examiner — Nicole C Shiflet
(74) *Attorney, Agent, or Firm* — Kilpatrick Townsend and Stockton LLP

(57) **CLAIM**

The ornamental design for a display screen or portion thereof with graphical user interface for selecting text with an abstraction tool, as shown and described.

DESCRIPTION

FIG. **1** is a front view of a first image in a sequence of a display screen or portion thereof with graphical user interface for selecting text with an abstraction tool showing our new design;
FIG. **2** is a front view of a second image thereof;
FIG. **3** is a front view of a third image thereof;
FIG. **4** is a front view of a fourth image thereof;
FIG. **5** is a front view of a fifth image thereof;
FIG. **6** is a front view of a sixth image thereof;
FIG. **7** is a front view of a seventh image thereof;
FIG. **8** is a front view of an eighth image thereof; and,
FIG. **9** is a front view of a ninth image thereof.
The outermost broken lined rectangles indicate a boundary of a display screen or a portion thereof and form no part of the claimed design. The broken lined text and characters form no part of the claimed design.
The appearance of the animated images sequentially transition from FIG. **1** to FIG. **9**. The process or period in which one image transitions to another forms no part of the claimed design.

1 Claim, 9 Drawing Sheets

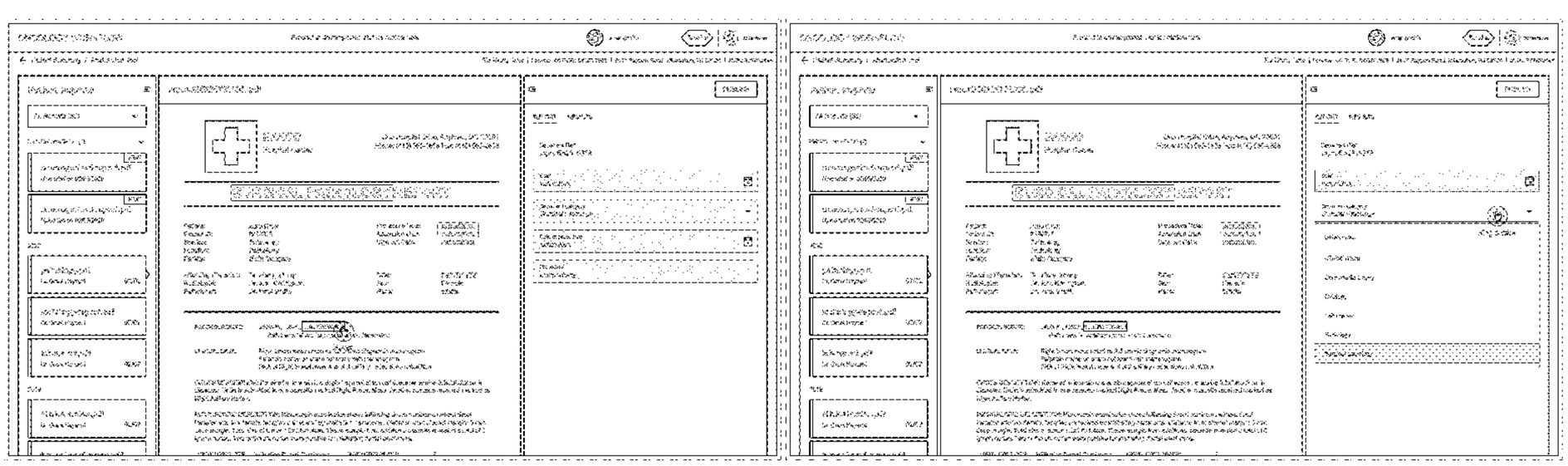

(56) **References Cited**

U.S. PATENT DOCUMENTS

D860,238	S	*	9/2019	Bhardwaj	D14/488
D868,104	S	*	11/2019	Christiana	D14/488
D871,443	S	*	12/2019	Christiana	D14/488
D874,481	S	*	2/2020	Kumar	D14/485
D881,211	S	*	4/2020	Marohn	D14/486
D888,739	S	*	6/2020	Christiana	D14/486
D890,199	S	*	7/2020	Kumar	D14/486
D892,849	S	*	8/2020	Sharma	D14/488
D902,226	S	*	11/2020	Burnell	D14/486
D905,734	S	*	12/2020	Christiana	D14/488
D906,360	S	*	12/2020	Eissa	D14/488
D922,420	S	*	6/2021	Castle	D14/486
D930,022	S	*	9/2021	Xie	D14/486
D931,314	S	*	9/2021	Xie	D14/486
D936,078	S	*	11/2021	Singh	D14/485
D940,172	S	*	1/2022	Xie	D14/486
2016/0349949	A1	*	12/2016	Miller	G06F 16/328
2019/0391825	A1	*	12/2019	Jann	G06F 3/0482

* cited by examiner

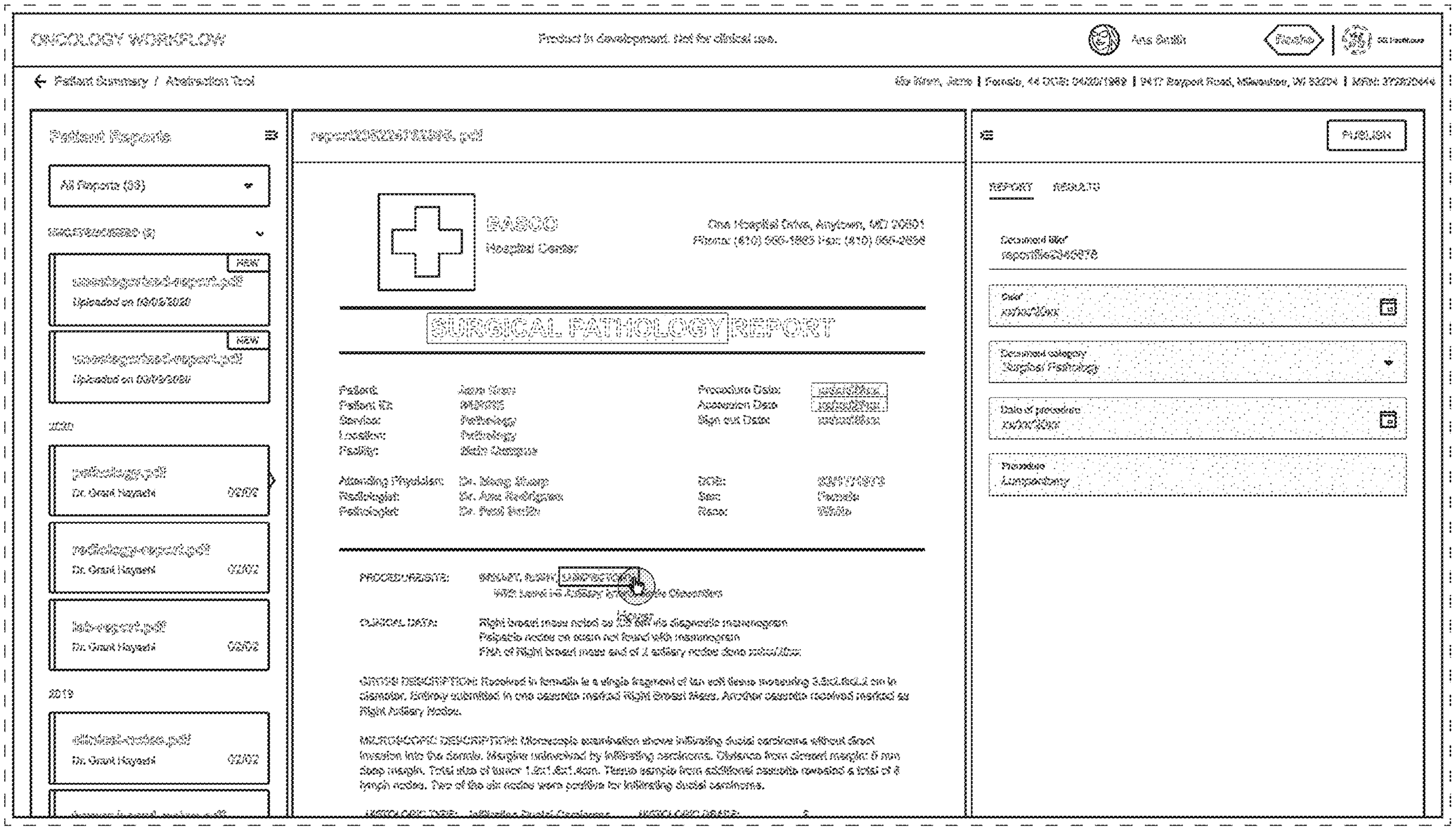
ONCOLOGY WORKFLOW
Product in development. Not for clinical use.
Ana Smith
Roche
Patient Summary / Abstraction Tool
Patient Reports
All Reports (33)
NEW
Uploaded on 10/05/2020
NEW
Uploaded on 09/03/2021
2020
pathology.pdf
Dr. Grant Hayashi 02/02
radiology-report.pdf
Dr. Grant Hayashi 02/02
lab-report.pdf
Dr. Grant Hayashi 02/02
2019
clinical-notes.pdf
Dr. Grant Hayashi 02/02
BASCO
Hospital Center
SURGICAL PATHOLOGY REPORT
Patient:
Jane Kren
Service:
Pathology
Location:
Pathology
Facility:
Main Campus
Procedure Date:
Accession Date
Sign out Date:
Attending Physician:
Dr. Meng Sharp
Radiologist:
Dr. Ana Rodriguez
Pathologist:
Dr. Paul Smith
DOB:
Sex:
Female
Race:
White
PROCEDURE SITE:
CLINICAL DATA:
Right breast mass noted on
diagnostic mammogram
Palpable nodes on exam not found with mammogram
FNA of Right breast mass and of 2 axillary nodes done
GROSS DESCRIPTION: Received in formalin is a single fragment of fat with tissue measuring
in dimension. Entirely submitted in one cassette marked Right Breast Mass. Another cassette received marked as Right Axillary Nodes.
MICROSCOPIC DESCRIPTION: Microscopic examination shows infiltrating ductal carcinoma without direct invasion into the dermis. Margins uninvolved by infiltrating carcinoma. Distance from closest margin: 8 mm deep margin. Total size of tumor 1.2x1.6x1.4cm. Tissue sample from additional cassette revealed a total of 6 lymph nodes. Two of the six nodes were positive for infiltrating ductal carcinoma.
PUBLISH
REPORT
RESULTS
Document title*
Date*
Document category
Surgical Pathology
Date of procedure
Provider
Lumpectomy

FIG. 1

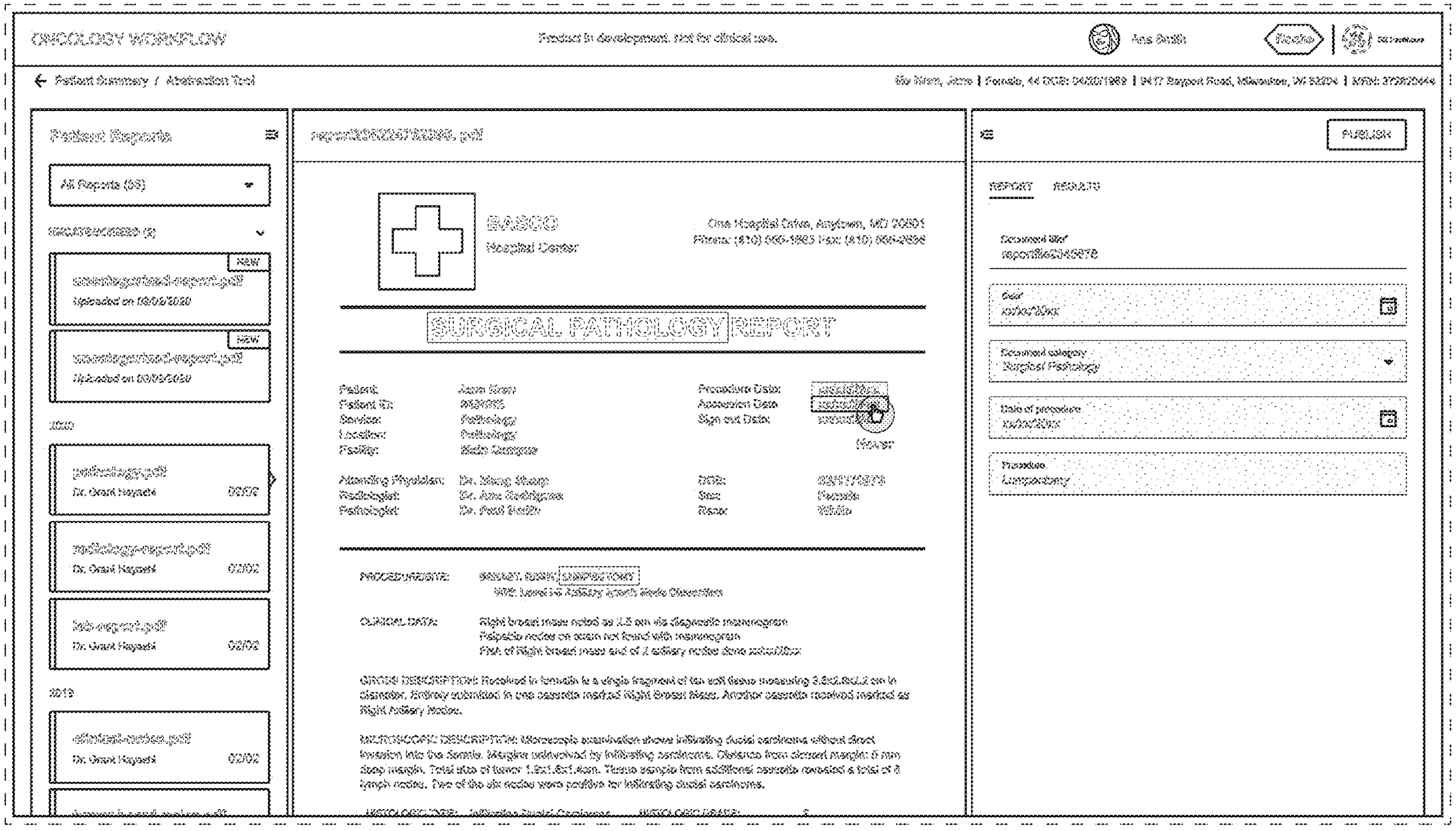
ONCOLOGY WORKFLOW
Product in development. Not for clinical use.
Ana Smith
Patient Summary / Abstraction Tool
Patient Reports
All Reports (53)
NEW
NEW
2020
pathology.pdf
Dr. Grant Hayashi
02/02
radiology-report.pdf
Dr. Grant Hayashi
02/02
lab-report.pdf
Dr. Grant Hayashi
02/02
2019
clinical-notes.pdf
Dr. Grant Hayashi
02/02
BASCO
Hospital Center
One Hospital Drive, Anytown, MD 20801
SURGICAL PATHOLOGY REPORT
Patient:
Patient ID:
Service:
Location:
Facility:
Procedure Date:
Accession Date
Sign out Date:
Hover
Attending Physician:
Radiologist:
Pathologist:
Dr. Mary Sharp
Dr. Ana Rodriguez
Dr. Paul Smith
DOB:
Sex:
Race:
Female
White
PROCEDURE(S):
CLINICAL DATA:
Right breast mass noted as 2.5 cm via diagnostic mammogram
Palpable nodes on exam not found with mammogram
FNA of Right breast mass and of 2 axillary nodes done concurrently
GROSS DESCRIPTION: Received in formalin is a single fragment of tan soft tissue measuring 3.5x2.5x1.2 cm in diameter. Entirely submitted in one cassette marked Right Breast Mass. Another cassette received marked as Right Axillary Nodes.
MICROSCOPIC DESCRIPTION: Microscopic examination shows infiltrating ductal carcinoma without direct invasion into the dermis. Margins uninvolved by infiltrating carcinoma. Distance from closest margin: 5 mm deep margin. Total size of tumor: 1.8x1.6x1.4cm. Tissue sample from additional cassette revealed a total of 6 lymph nodes. Five of the six nodes were positive for infiltrating ductal carcinoma.
PUBLISH
REPORT
RESULTS
Document title
Date
Document category
Surgical Pathology
Date of procedure
Procedure
Lumpectomy

FIG. 2

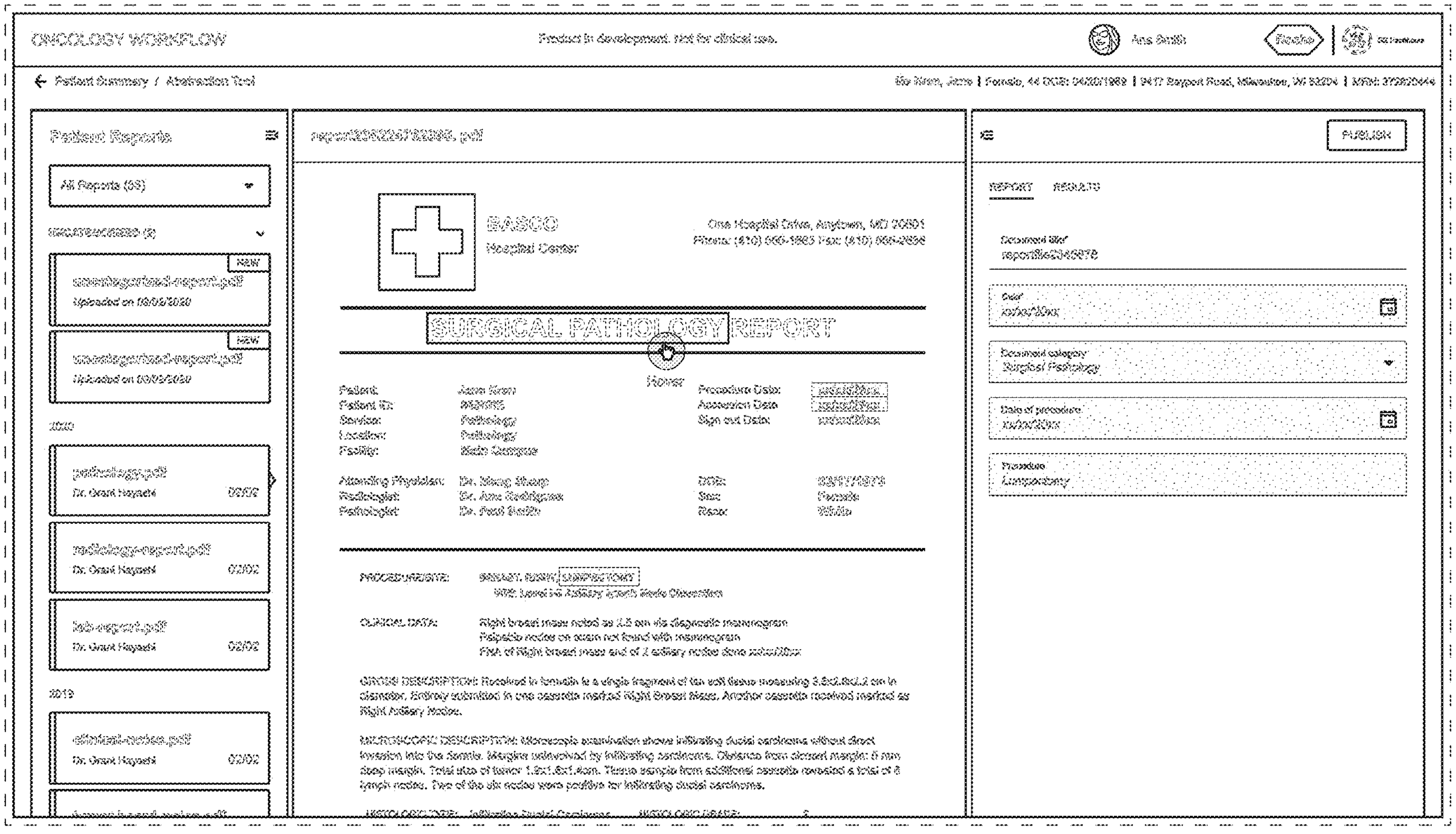
ONCOLOGY WORKFLOW
Product in development. Not for clinical use.
Ana Smith
Roche
Patient Summary / Abstraction Tool
Patient Reports
All Reports (53)
NEW
uncategorized-report.pdf
Uploaded on 10/03/2020
NEW
uncategorized-report.pdf
Uploaded on 10/03/2020
2020
pathology.pdf
Dr. Grant Hayashi 02/02
radiology-report.pdf
Dr. Grant Hayashi 02/02
lab-report.pdf
Dr. Grant Hayashi 02/02
2019
clinical-notes.pdf
Dr. Grant Hayashi 02/02
report2352257622384.pdf
BASCO
Hospital Center
One Hospital Drive, Anytown, MD 20801
SURGICAL PATHOLOGY REPORT
Hover
Patient: Jane Kren
Patient ID: 9531115
Service: Pathology
Location: Pathology
Facility: Main Campus
Procedure Date:
Accession Date
Sign out Date:
Attending Physician: Dr. Meng Sharp
Radiologist: Dr. Ana Rodriguez
Pathologist: Dr. Paul Smith
DOB:
Sex: Female
Race: White
PROCEDURE(S):
CLINICAL DATA:
PUBLISH
REPORT
RESULTS
Document title*
report2352257622384
Date*
Document category*
Surgical Pathology
Date of procedure*
Procedure
Lumpectomy

FIG. 3

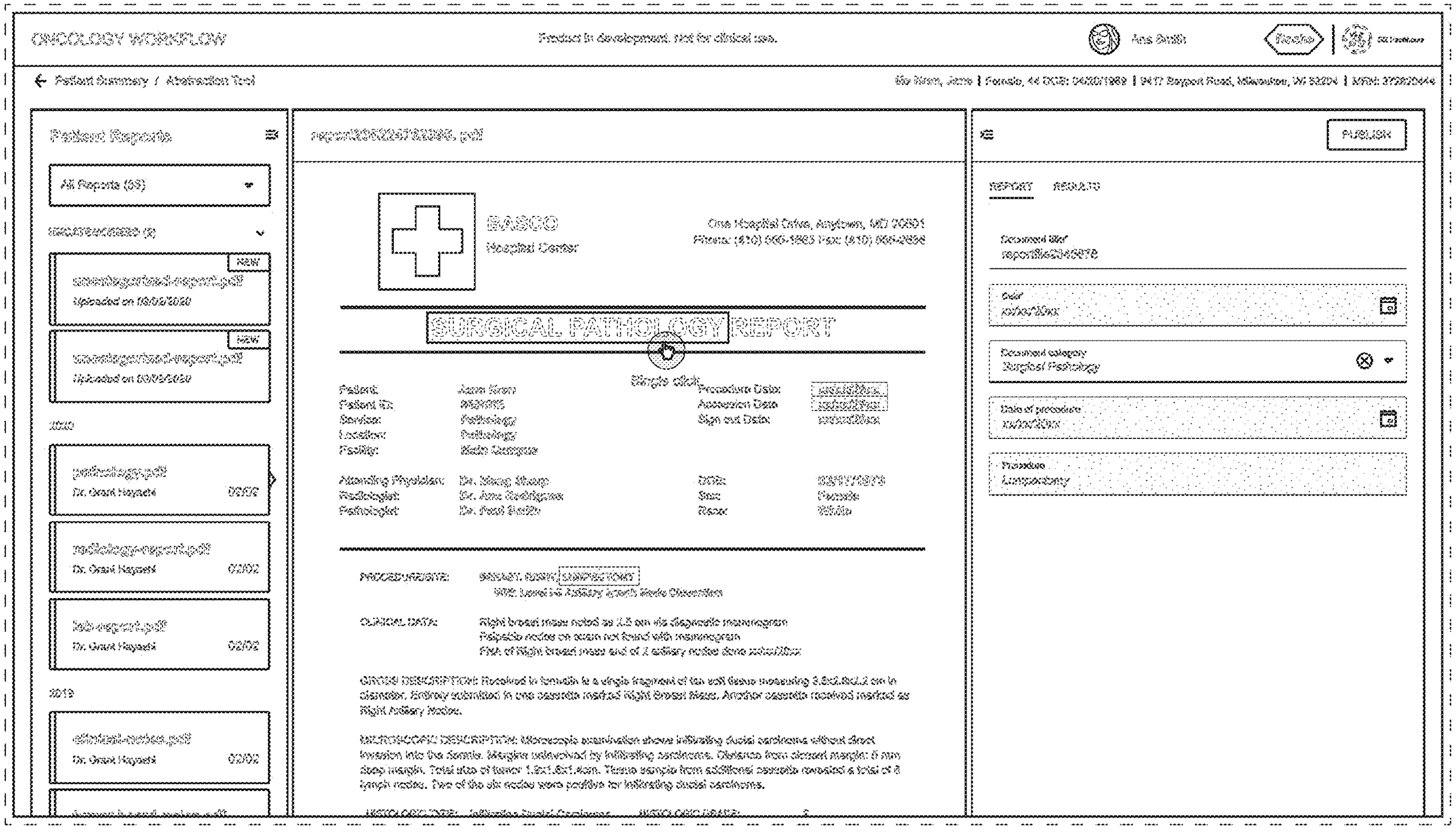
ONCOLOGY WORKFLOW
Product in development. Not for clinical use.
Ana Smith
Roche
Patient Summary / Abstraction Tool
Patient Reports
All Reports (53)
NEW
uncategorized-report.pdf
Uploaded on 10/03/2020
NEW
uncategorized-report.pdf
Uploaded on 09/03/2020
2020
pathology.pdf
Dr. Grant Hayashi 02/02
radiology-report.pdf
Dr. Grant Hayashi 02/02
lab-report.pdf
Dr. Grant Hayashi 02/02
2019
clinical-notes.pdf
Dr. Grant Hayashi 02/02
report2352257622384.pdf
BASCO
Hospital Center
One Hospital Drive, Anytown, MD 20801
Phone: (410) 666-1863 Fax: (410) 666-2656
SURGICAL PATHOLOGY REPORT
Simple click
Patient: Jane Kren
Patient ID: 9531115
Service: Pathology
Location: Pathology
Facility: Main Campus
Procedure Date:
Accession Date
Sign out Date:
Attending Physician: Dr. Meng Sharp
Radiologist: Dr. Ana Rodriguez
Pathologist: Dr. Paul Smith
DOB:
Sex: Female
Race: White
PROCEDURE(S):
CLINICAL DATA:
Right breast mass noted as 2.5 cm via diagnostic mammogram
Palpable nodes on exam not found with mammogram
FNA of Right breast mass and of 2 axillary nodes done
GROSS DESCRIPTION: Received in formalin is a single fragment of fat with tissue measuring
in diameter. Entirely submitted in one cassette marked Right Breast Mass. Another cassette received marked as Right Axillary Nodes.
MICROSCOPIC DESCRIPTION: Microscopic examination shows infiltrating ductal carcinoma without direct invasion into the dermis. Margins uninvolved by infiltrating carcinoma. Distance from closest margin: 8 mm deep margin. Total size of tumor
Tissue sample from additional cassette revealed a total of 8 lymph nodes. Five of the six nodes were positive for infiltrating ductal carcinoma.
PUBLISH
REPORT
RESULTS
Document title
Date
Document category
Surgical Pathology
Date of procedure
Procedure
Lumpectomy

FIG. 4

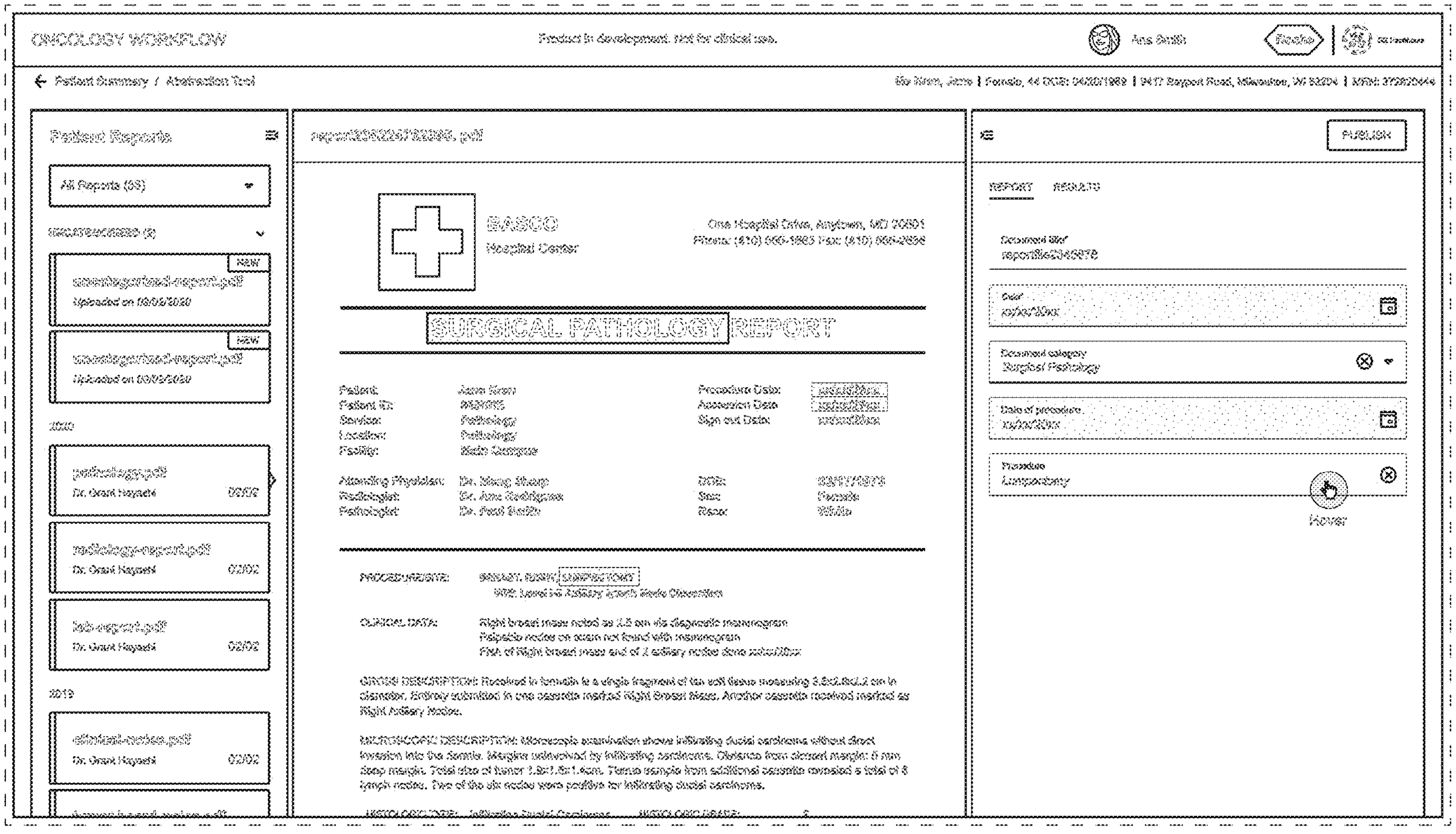
ONCOLOGY WORKFLOW
Product in development. Not for clinical use.
Ana Smith
Roche
Patient Summary / Abstraction Tool
Patient Reports
All Reports (53)
NEW
uncategorized-report.pdf
Uploaded on 10/03/2020
NEW
uncategorized-report.pdf
Uploaded on 10/03/2020
2020
pathology.pdf
Dr. Grant Hayashi 02/02
radiology-report.pdf
Dr. Grant Hayashi 02/02
lab-report.pdf
Dr. Grant Hayashi 02/02
2019
clinical-notes.pdf
Dr. Grant Hayashi 02/02
report2023225782384.pdf
BASCO
Hospital Center
One Hospital Drive, Anytown, MD 20801
SURGICAL PATHOLOGY REPORT
Patient: Jane Kren
Patient ID: 9831875
Service: Pathology
Location: Pathology
Facility: Main Campus
Procedure Date:
Accession Date
Sign out Date:
Attending Physician: Dr. Meng Sharp
Radiologist: Dr. Ana Rodriguez
Pathologist: Dr. Paul Smith
DOB:
Sex: Female
Race: White
PROCEDURE(S):
CLINICAL DATA:
PUBLISH
REPORT
RESULTS
Document title
Date
Document category
Surgical Pathology
Date of procedure
Procedure
Lumpectomy
Hover

FIG. 5

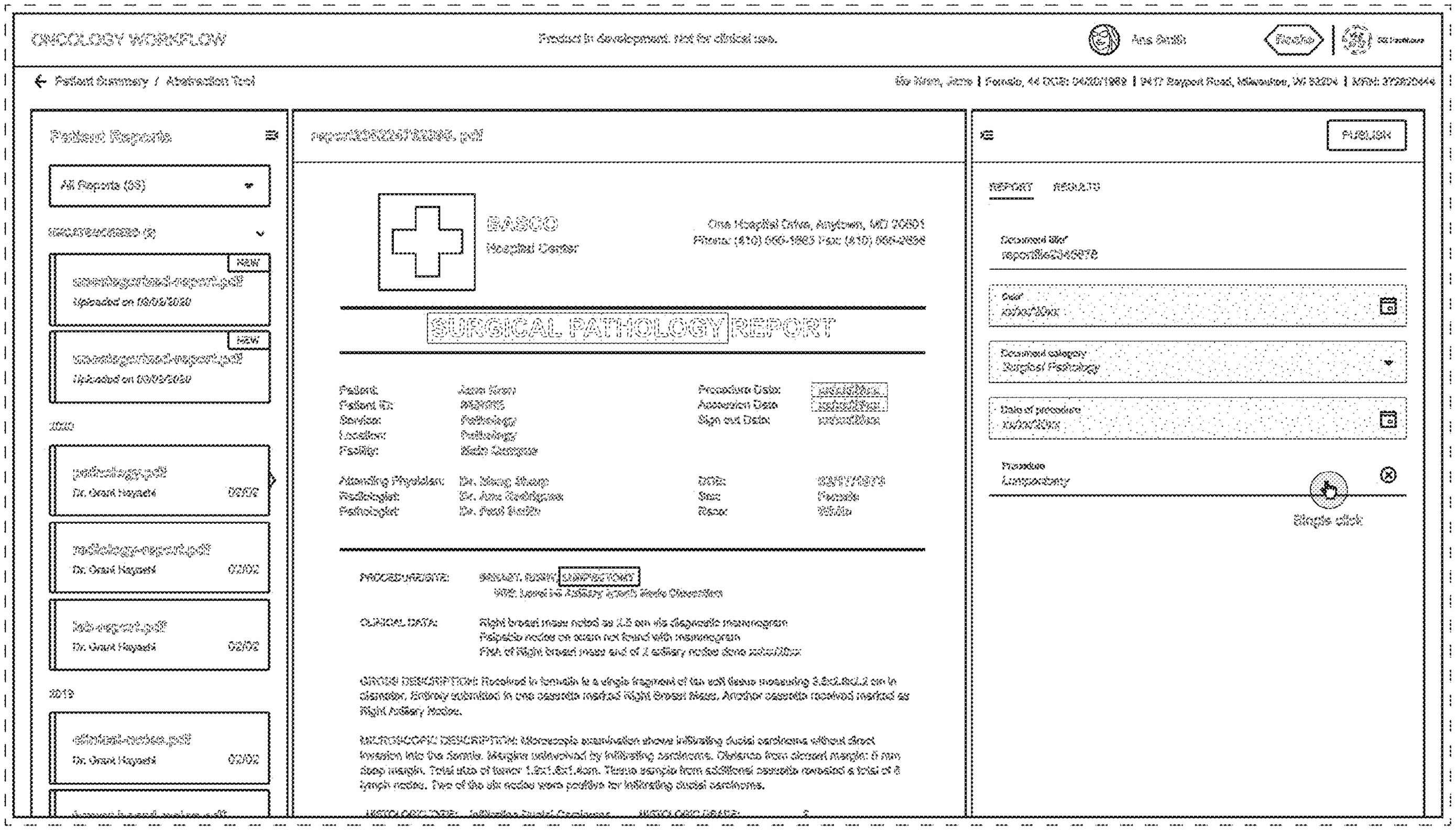
ONCOLOGY WORKFLOW
Product in development. Not for clinical use.
Ana Smith
Patient Summary / Abstraction Tool
Patient Reports
All Reports (53)
NEW
uncategorized-report.pdf
Uploaded on 10/03/2020
NEW
uncategorized-report.pdf
Uploaded on 10/03/2020
2020
pathology.pdf
Dr. Grant Hayashi 02/02
radiology-report.pdf
Dr. Grant Hayashi 02/02
lab-report.pdf
Dr. Grant Hayashi 02/02
2019
clinical-notes.pdf
Dr. Grant Hayashi 02/02
report2062257622864.pdf
BASCO
Hospital Center
One Hospital Drive, Anytown, MD 20801
Phone: (410) 666-1863 Fax: (410) 666-2656
SURGICAL PATHOLOGY REPORT
Patient: Jane Kren
Patient ID: 9639875
Service: Pathology
Location: Pathology
Facility: Main Campus
Procedure Date:
Accession Date
Sign out Date:
Attending Physician: Dr. Meng Sharp
Radiologist: Dr. Ana Rodriguez
Pathologist: Dr. Paul Smith
DOB:
Sex: Female
Race: White
PROCEDURE(S):
CLINICAL DATA:
PUBLISH
REPORT
RESULTS
Document title*
report8642876
Date*
Document category
Surgical Pathology
Date of procedure
Procedure
Lumpectomy
Single click

FIG. 6

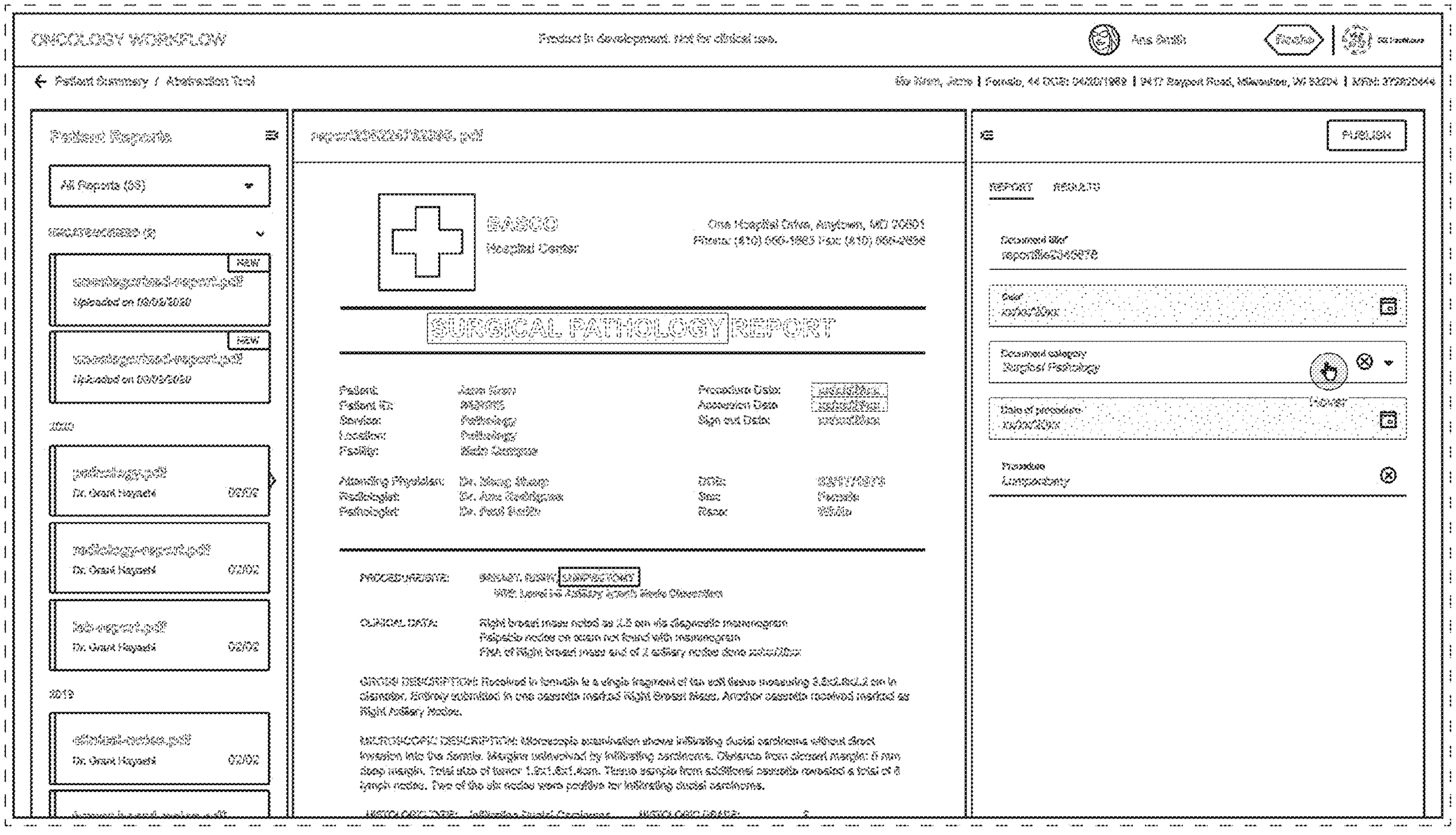
ONCOLOGY WORKFLOW
Product in development. Not for clinical use.
Ana Smith
Roche
Patient Summary / Abstraction Tool
Patient Reports
All Reports (53)
NEW
uncategorized-report.pdf
Uploaded on 10/03/2020
NEW
uncategorized-report.pdf
Uploaded on 10/03/2020
2020
pathology.pdf
Dr. Grant Hayashi 02/02
radiology-report.pdf
Dr. Grant Hayashi 02/02
lab-report.pdf
Dr. Grant Hayashi 02/02
2019
clinical-notes.pdf
Dr. Grant Hayashi 02/02
report2023225782384.pdf
BASCO
Hospital Center
One Hospital Drive, Anytown, MD 20801
SURGICAL PATHOLOGY REPORT
Patient:
Patient ID:
Service:
Location:
Facility:
Procedure Date:
Accession Date
Sign out Date:
Attending Physician:
Radiologist:
Pathologist:
DOB:
Sex:
Race:
Female
White
PROCEDURE(S):
CLINICAL DATA:
GROSS DESCRIPTION:
MICROSCOPIC DESCRIPTION:
PUBLISH
REPORT
RESULTS
Document title
Date
Document category
Surgical Pathology
Date of procedure
Procedure
Lumpectomy
Hover

FIG. 7

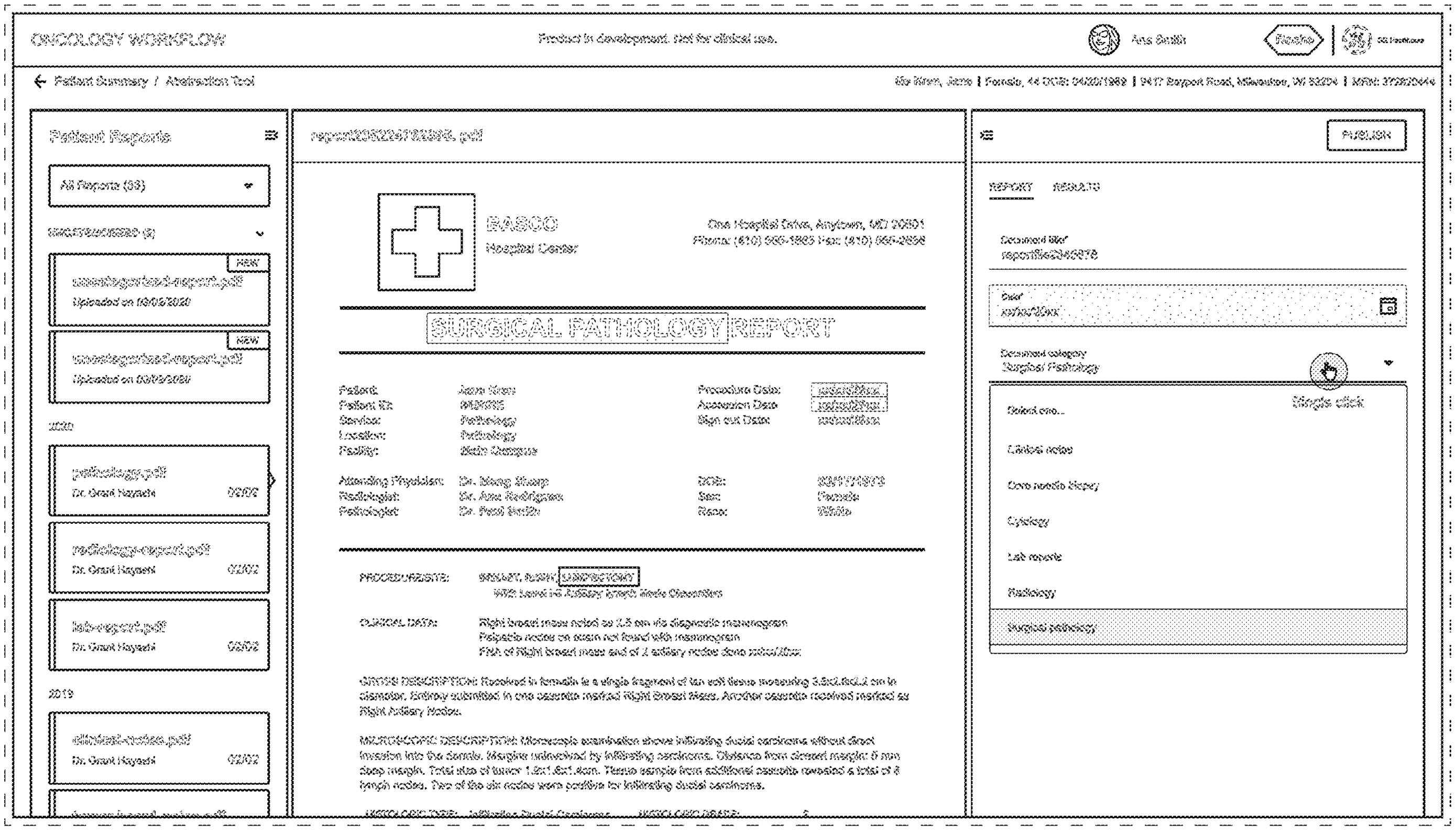
ONCOLOGY WORKFLOW
Product in development. Not for clinical use.
Ana Smith
Roche
Patient Summary / Abstraction Tool
Patient Reports
All Reports (33)
NEW
Uploaded on 10/05/2020
NEW
Uploaded on 10/05/2020
2020
pathology.pdf
Dr. Grant Hayashi 02/02
radiology-report.pdf
Dr. Grant Hayashi 02/02
lab-report.pdf
Dr. Grant Hayashi 02/02
2019
clinical-notes.pdf
Dr. Grant Hayashi 02/02
report2052247023894.pdf
BASCO
Hospital Center
One Hospital Drive, Anytown, MD 20801
Phone: (410) 666-1863 Fax: (410) 666-2658
SURGICAL PATHOLOGY REPORT
Patient: Jane Kren
Patient ID: 8876785
Service: Pathology
Location: Pathology
Facility: Main Campus
Procedure Date: 10/01/2020
Accession Date: 10/02/2020
Sign out Date: 10/04/2020
Attending Physician: Dr. Meng Sharp
Radiologist: Dr. Ana Rodriguez
Pathologist: Dr. Paul Smith
DOB: 03/17/1973
Sex: Female
Race: White
PROCEDURE SITE: SIMULT, RIGHT UNSPECIFIED
With Level I-II Axillary lymph node Dissection
CLINICAL DATA: Right breast mass noted on 2.5 cm via diagnostic mammogram
Palpable nodes on exam not found with mammogram
FNA of Right breast mass and of 2 axillary nodes done 10/01/20xx
GROSS DESCRIPTION: Received in formalin is a single fragment of fan soft tissue measuring 3.5x2.5x0.2 cm in diameter. Entirely submitted in one cassette marked Right Breast Mass. Another cassette received marked as Right Axillary Nodes.
MICROSCOPIC DESCRIPTION: Microscopic examination shows infiltrating ductal carcinoma without direct invasion into the dermis. Margins uninvolved by infiltrating carcinoma. Distance from closest margin: 8 mm deep margin. Total size of tumor 1.2x1.6x1.4cm. Tissue sample from additional cassette revealed a total of 6 lymph nodes. Two of the six nodes were positive for infiltrating ductal carcinoma.
PUBLISH
REPORT
RESULTS
Document title
report#ac2346878
Date
10/10/20xx
Document category
Surgical Pathology
Select one...
Clinical notes
Core needle biopsy
Cytology
Lab reports
Radiology
Surgical pathology
Single click

FIG. 8

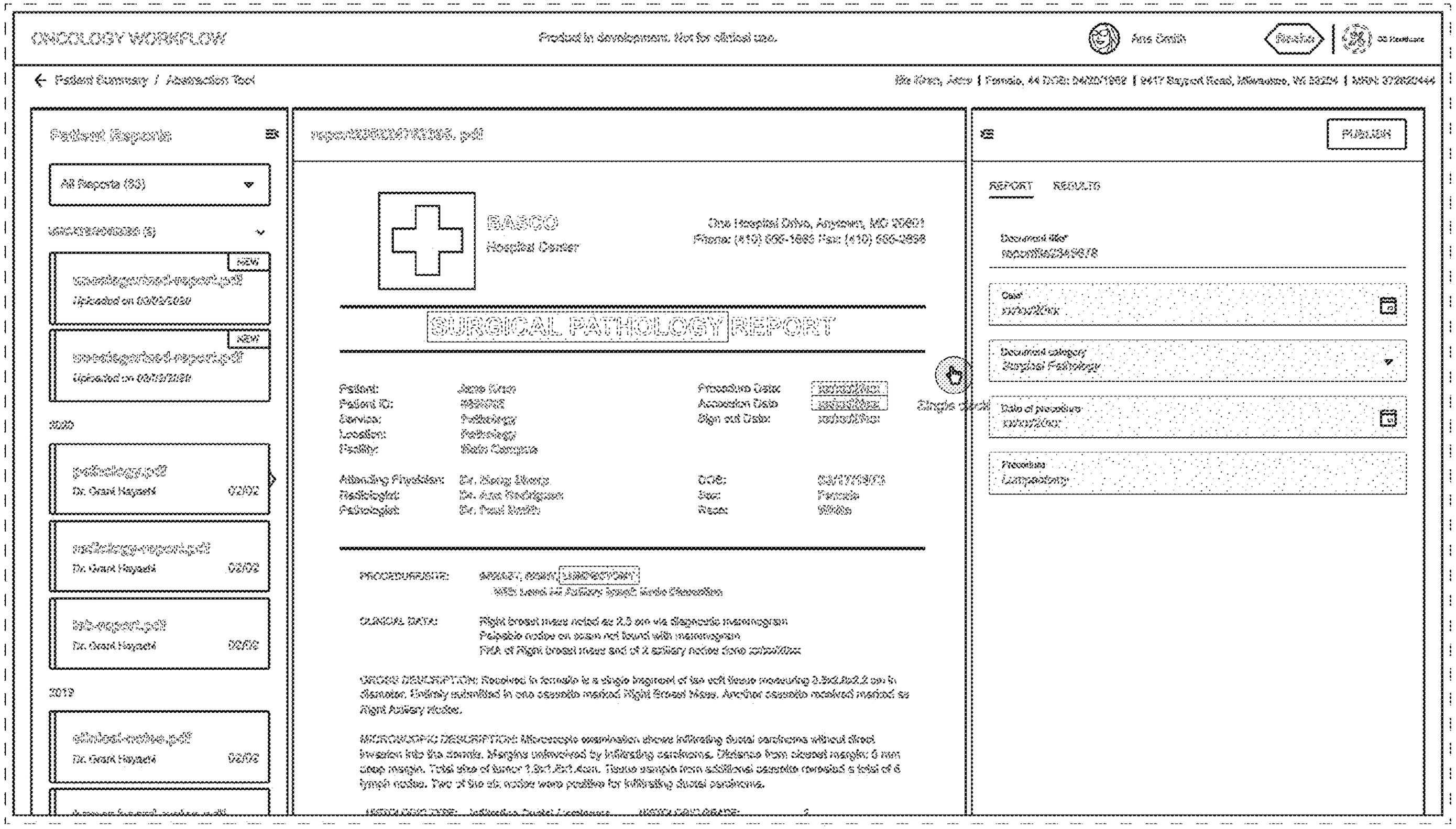
ONCOLOGY WORKFLOW
Product in development. Not for clinical use.
Patient Summary / Abstraction Tool
Patient Reports
All Reports (33)
NEW
2020
pathology.pdf
Dr. Grant Hayashi 02/02
radiology-report.pdf
Dr. Grant Hayaski 02/02
lab-report.pdf
Dr. Grant Hayashi 02/02
2019
clinical-notes.pdf
Dr. Grant Hayashi 02/02
report20382247623365.pdf
BASCO
Hospital Center
One Hospital Drive, Anytown, MD 20601
SURGICAL PATHOLOGY REPORT
Patient:
Patient ID:
Service:
Location:
Facility:
Procedure Date:
Accession Date:
Sign out Date:
Attending Physician:
Radiologist:
Pathologist:
DOB:
Sex:
Race:
Single click
PUBLISH
REPORT
RESULTS
Document title*
Date*
Document category*
Surgical Pathology
Date of procedure*
Procedure
Lumpectomy

FIG. 9