US00D974392S

(12) United States Design Patent

Barnard et al.

(10) Patent No.: US D974,392 S
(45) Date of Patent: ** Jan. 3, 2023

(54) **DISPLAY SCREEN OR PORTION THEREOF WITH GRAPHICAL USER INTERFACE FOR MANUALLY ABSTRACTING TEXT WITH AN ABSTRACTION TOOL**

(71) Applicant: **Roche Molecular Systems, Inc.**, Pleasanton, CA (US)

(72) Inventors: **Cindy K. Barnard**, Santa Clara, CA (US); **Sambasivarao Byrapuneni**, Pleasanton, CA (US); **Diwakar Chapagain**, Cupertino, CA (US); **Archana P. Dorge**, Campbell, CA (US); **Catherine M. Jeu**, San Jose, CA (US); **Rengaraja Kesavan**, Pleasanton, CA (US); **Kaushal D. Parekh**, Redwood City, CA (US); **Raman Ramanathan**, San Jose, CA (US); **David M. Schlossman**, Columbia, MO (US); **Vishakha Sharma**, Foster City, CA (US)

(73) Assignee: **Roche Molecular Systems, Inc.**, Pleasanton, CA (US)

(**) Term: **15 Years**

(21) Appl. No.: **29/766,580**

(22) Filed: **Jan. 15, 2021**

(51) **LOC (14) Cl.** **14-04**

(52) **U.S. Cl.**
USPC **D14/486**

(58) **Field of Classification Search**
USPC D14/485–495
(Continued)

(56) **References Cited**

U.S. PATENT DOCUMENTS

D733,176 S * 6/2015 Lin D14/486
D809,530 S * 2/2018 Matheson D14/485
(Continued)

Primary Examiner — Sheryl Lane
Assistant Examiner — Nicole C Shiflet
(74) *Attorney, Agent, or Firm* — Kilpatrick Townsend and Stockton LLP

(57) **CLAIM**

The ornamental design for a display screen or portion thereof with graphical user interface for manually abstracting text with an abstraction tool, as shown and described.

DESCRIPTION

FIG. **1** is a front view of a first image in a sequence of a display screen or portion thereof with graphical user interface for manually abstracting text with an abstraction tool showing our new design;
FIG. **2** is a front view of a second image thereof;
FIG. **3** is a front view of a third image thereof;
FIG. **4** is a front view of a fourth image thereof;
FIG. **5** is a front view of a fifth image thereof;
FIG. **6** is a front view of a sixth image thereof;
FIG. **7** is a front view of a seventh image thereof;
FIG. **8** is a front view of an eighth image thereof;
FIG. **9** is a front view of a ninth image thereof;
FIG. **10** is a front view of a tenth image thereof;
FIG. **11** is a front view of an eleventh image thereof;
FIG. **12** is a front view of a twelfth image thereof;
FIG. **13** is a front view of a thirteenth image thereof;
FIG. **14** is a front view of a fourteenth image thereof;
FIG. **15** is a front view of a fifteenth image thereof;
FIG. **16** is a front view of a sixteenth image thereof;
FIG. **17** is a front view of a seventeenth image thereof;
FIG. **18** is a front view of an eighteenth image thereof; and,
FIG. **19** is a front view of a nineteenth image thereof.
The outermost broken lined rectangles indicate a boundary of a display screen or a portion thereof and form no part of the claimed design. The broken lined text and characters form no part of the claimed design.
The appearance of the animated images sequentially transition from FIG. **1** to FIG. **19**. The process or period in which one image transitions to another forms no part of the claimed design.

1 Claim, 19 Drawing Sheets

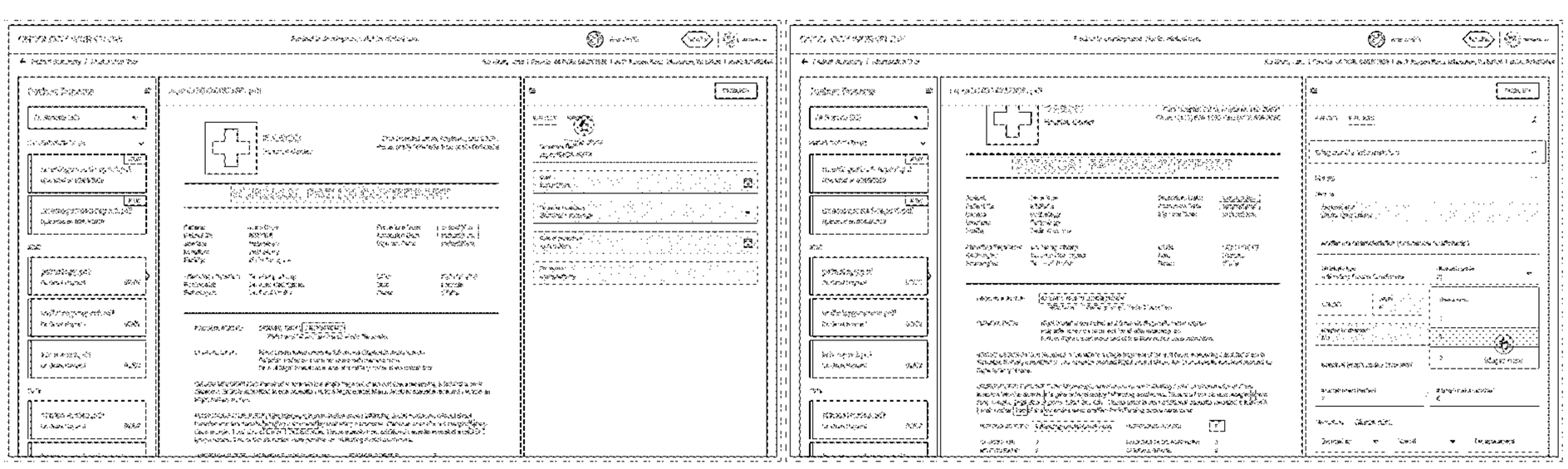

(58) **Field of Classification Search**
CPC G06F 3/048; G06F 3/0481; G06F 3/04817; G06F 3/0482; G06F 3/0483; G06F 3/04842; G06F 3/0485; G06F 3/04855; G06F 3/0486; G06F 3/0488; G06F 3/04886; G06F 9/451; G06F 40/103; G06F 40/106; G06F 40/189; G06F 40/191
See application file for complete search history.

(56) **References Cited**

U.S. PATENT DOCUMENTS

D836,652	S	*	12/2018	Fowler	D14/486
D841,031	S	*	2/2019	Orlando	D14/486
D860,238	S	*	9/2019	Bhardwaj	D14/488
D868,104	S	*	11/2019	Christiana	D14/488
D871,443	S	*	12/2019	Christiana	D14/488
D874,481	S	*	2/2020	Kumar	D14/485
D881,211	S	*	4/2020	Marohn	D14/486
D888,739	S	*	6/2020	Christiana	D14/486
D890,199	S	*	7/2020	Kumar	D14/486
D892,849	S	*	8/2020	Sharma	D14/488
D902,226	S	*	11/2020	Burnell	D14/486
D905,734	S	*	12/2020	Christiana	D14/488
D906,360	S	*	12/2020	Eissa	D14/488
D922,420	S	*	6/2021	Castle	D14/486
D930,022	S	*	9/2021	Xie	D14/486
D931,314	S	*	9/2021	Xie	D14/486
D936,078	S	*	11/2021	Singh	D14/485
D940,172	S	*	1/2022	Xie	D14/486
2016/0349949	A1	*	12/2016	Miller	G06F 16/328
2019/0391825	A1	*	12/2019	Jann	G06F 3/0482

* cited by examiner

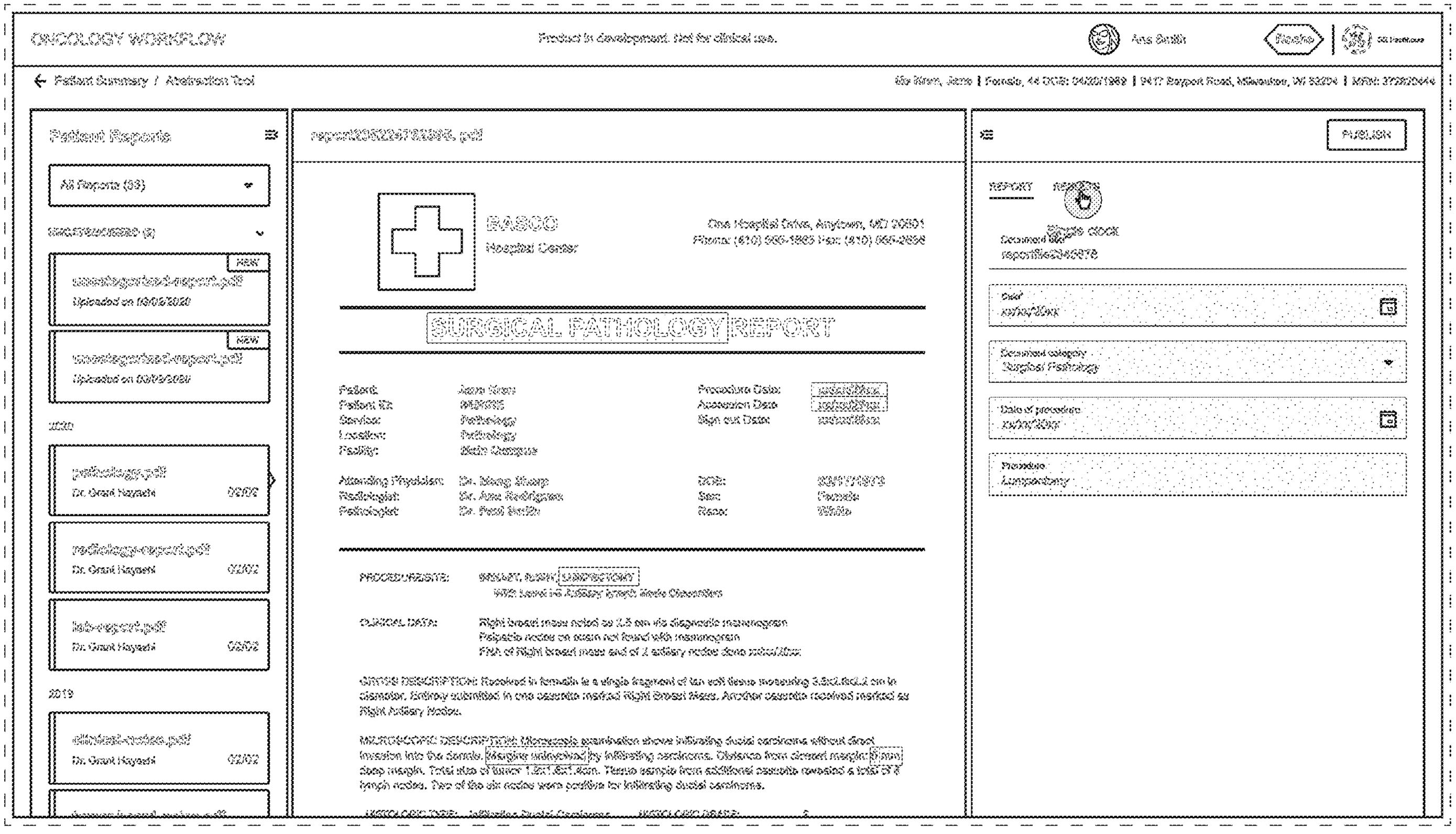
ONCOLOGY WORKFLOW
Product in development. Not for clinical use.
Ana Smith
Roche
Patient Summary / Abstraction Tool
Patient Reports
All Reports (33)
NEW
Uploaded on 10/05/2020
NEW
Uploaded on 09/03/2021
2020
pathology.pdf
Dr. Grant Hayashi 02/02
radiology-report.pdf
Dr. Grant Hayashi 02/02
lab-report.pdf
Dr. Grant Hayashi 02/02
2019
clinical-notes.pdf
Dr. Grant Hayashi 02/02
report2052247023894.pdf
BASCO
Hospital Center
One Hospital Drive, Anytown, MD 20801
Phone: (410) 666-1863 Fax: (410) 666-2658
SURGICAL PATHOLOGY REPORT
Patient: Jane Kren
Patient ID: 9876785
Service: Pathology
Location: Pathology
Facility: Main Campus
Procedure Date: 10/01/2020
Accession Date: 10/02/2020
Sign out Date: 10/04/2020
Attending Physician: Dr. Meng Sharp
Radiologist: Dr. Ana Rodriguez
Pathologist: Dr. Paul Smith
DOB: 03/17/1973
Sex: Female
Race: White
PROCEDURE(S):
CLINICAL DATA:
GROSS DESCRIPTION:
MICROSCOPIC DESCRIPTION:
PUBLISH
REPORT
Document ID
Date
Document category
Surgical Pathology
Date of procedure
Provider
Lumpectomy

FIG. 1

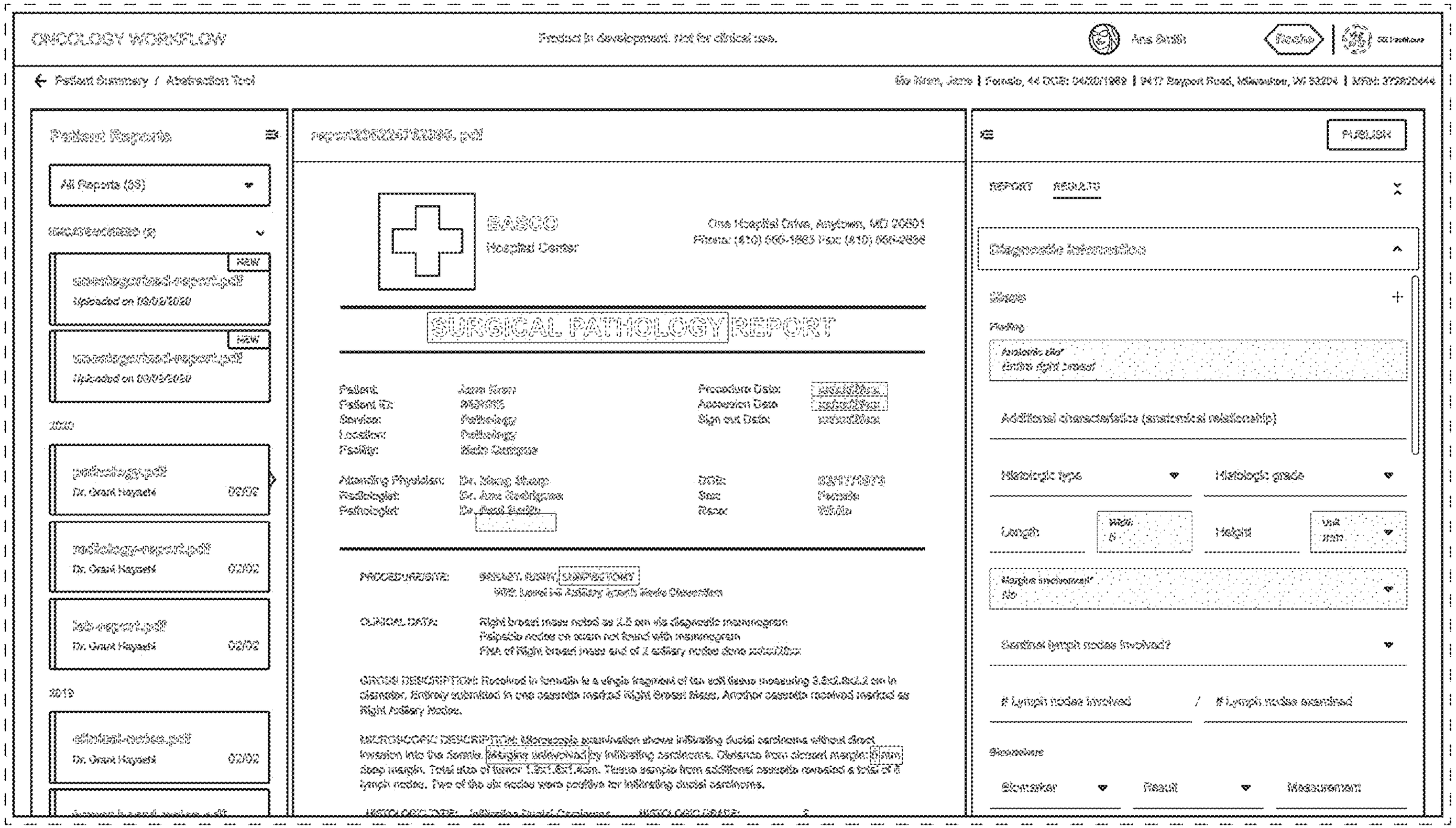
ONCOLOGY WORKFLOW
Product in development. Not for clinical use.
Ana Smith
Patient Summary / Abstraction Tool
Patient Reports
All Reports (53)
NEW
uncategorized-report.pdf
Uploaded on 10/03/2020
NEW
uncategorized-report.pdf
Uploaded on 09/03/2020
2020
pathology.pdf
Dr. Grant Hayashi 02/02
radiology-report.pdf
Dr. Grant Hayashi 02/02
lab-report.pdf
Dr. Grant Hayashi 02/02
2019
clinical-notes.pdf
Dr. Grant Hayashi 02/02
report20522257622884.pdf
BASCO
Hospital Center
One Hospital Drive, Anytown, MD 70801
Phone: (410) 666-1863 Fax: (410) 666-2656
SURGICAL PATHOLOGY REPORT
Patient: Jane Kren
Patient ID: 9634315
Service: Pathology
Location: Pathology
Facility: Main Campus
Procedure Date:
Accession Date
Sign out Date:
Attending Physician: Dr. Meng Sharp
Radiologist: Dr. Ana Rodriguez
Pathologist: Dr. Ana Smith
DOB:
Sex: Female
Race: White
PROCEDURE(S):
CLINICAL DATA:
Right breast mass noted as 4.5 cm via diagnostic mammogram
Palpable nodes on exam not found with mammogram
FNA of Right breast mass and of 2 axillary nodes done
GROSS DESCRIPTION: Received in formalin is a single fragment of fan soft tissue measuring
in diameter. Entirely submitted in one cassette marked Right Breast Mass. Another cassette received marked as Right Axillary Nodes.
MICROSCOPIC DESCRIPTION: Microscopic examination shows infiltrating ductal carcinoma without direct invasion into the dermis. Margins uninvolved by infiltrating carcinoma. Distance from closest margin:
deep margin. Total size of tumor
Tissue sample from additional cassette revealed a total of 6 lymph nodes. Two of the six nodes were positive for infiltrating ductal carcinoma.
PUBLISH
REPORT
RESULTS
Diagnostic Information
Biopsy
Finding
Additional characteristics (anatomical relationship)
Histologic type
Histologic grade
Length
Height
Margins involved?
No
Sentinel lymph nodes involved?
Lymph nodes involved
Lymph nodes examined
Biomarkers
Biomarker
Result
Measurement

FIG. 2

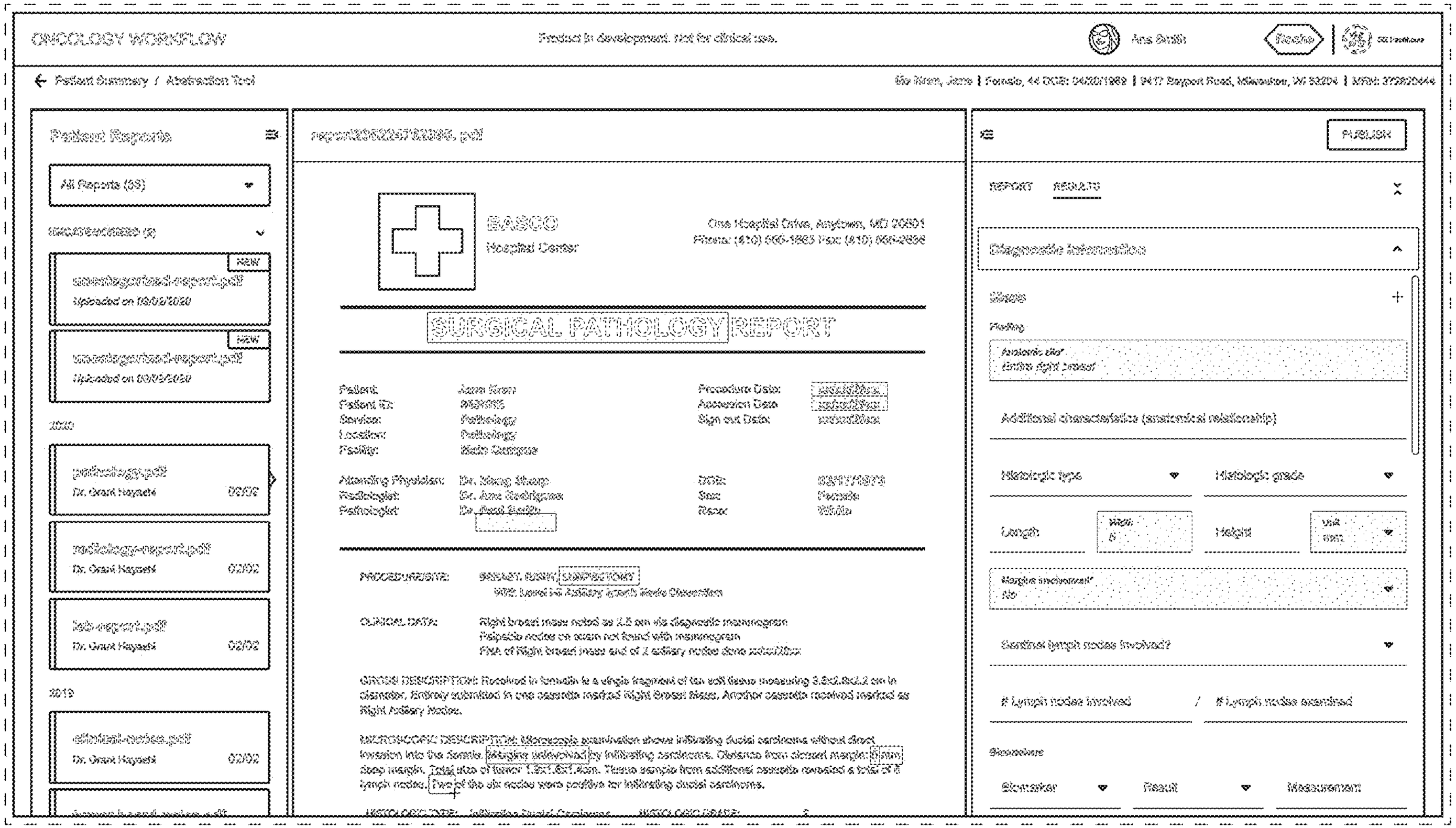
ONCOLOGY WORKFLOW
Product in development. Not for clinical use.
Ana Smith
Patient Summary / Abstraction Tool
Patient Reports
All Reports (53)
NEW
NEW
2020
pathology.pdf
Dr. Grant Hayashi 02/02
radiology-report.pdf
Dr. Grant Hayashi 02/02
lab-report.pdf
Dr. Grant Hayashi 02/02
2019
clinical-notes.pdf
Dr. Grant Hayashi 02/02
BASCO
Hospital Center
SURGICAL PATHOLOGY REPORT
PUBLISH
REPORT
RESULTS
Diagnostic Information
Sites
Additional characteristics (anatomical relationship)
Histologic type
Histologic grade
Length
Height
Sentinel lymph nodes involved?
Lymph nodes involved
Lymph nodes examined
Biomarkers
Biomarker
Result
Measurement

FIG. 3

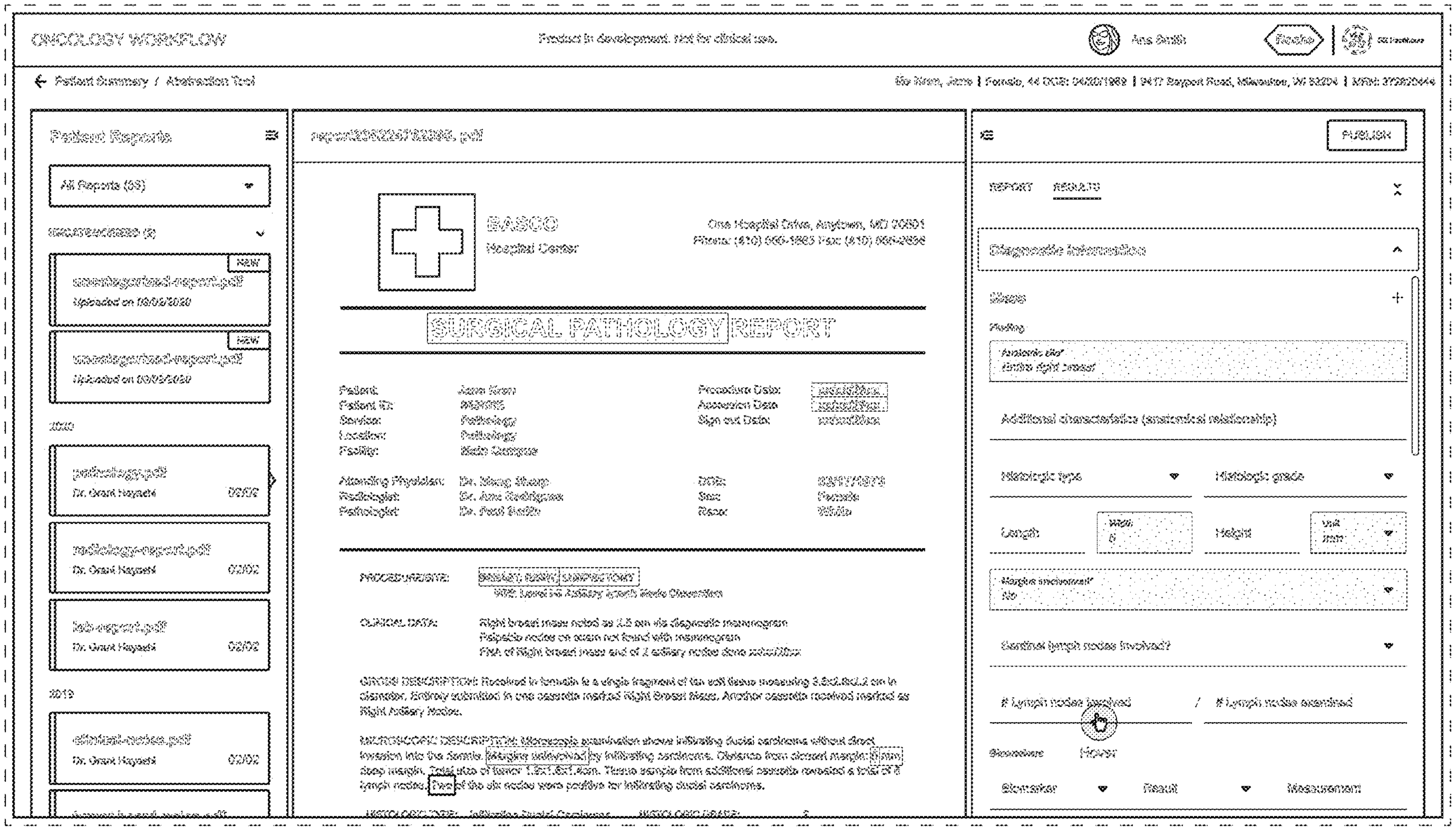
ONCOLOGY WORKFLOW
Product in development. Not for clinical use.
Ana Smith
Patient Summary / Abstraction Tool
Patient Reports
All Reports (53)
NEW
uncategorized-report.pdf
Uploaded on 10/03/2020
NEW
uncategorized-report.pdf
Uploaded on 09/03/2020
2020
pathology.pdf
Dr. Grant Hayashi 02/02
radiology-report.pdf
Dr. Grant Hayashi 02/02
lab-report.pdf
Dr. Grant Hayashi 02/02
2019
clinical-notes.pdf
Dr. Grant Hayashi 02/02
report20522257622884.pdf
BASCO
Hospital Center
One Hospital Drive, Anytown, MD 70801
SURGICAL PATHOLOGY REPORT
Patient: Jane Kren
Patient ID: 9934385
Service: Pathology
Location: Pathology
Facility: Main Campus
Procedure Date:
Accession Date:
Sign out Date:
Attending Physician: Dr. Meng Sharp
Radiologist: Dr. Ana Rodriguez
Pathologist: Dr. Paul Smith
DOB:
Sex: Female
Race: White
PROCEDURE(S):
CLINICAL DATA:
GROSS DESCRIPTION:
MICROSCOPIC DESCRIPTION:
PUBLISH
REPORT
RESULTS
Diagnostic Information
Blocks
Finding
Additional characteristics (anatomical relationship)
Histologic type
Histologic grade
Length
Height
Margins involved?
Sentinel lymph nodes involved?
Lymph nodes involved
Lymph nodes examined
Biomarker
Result
Measurement

FIG. 4

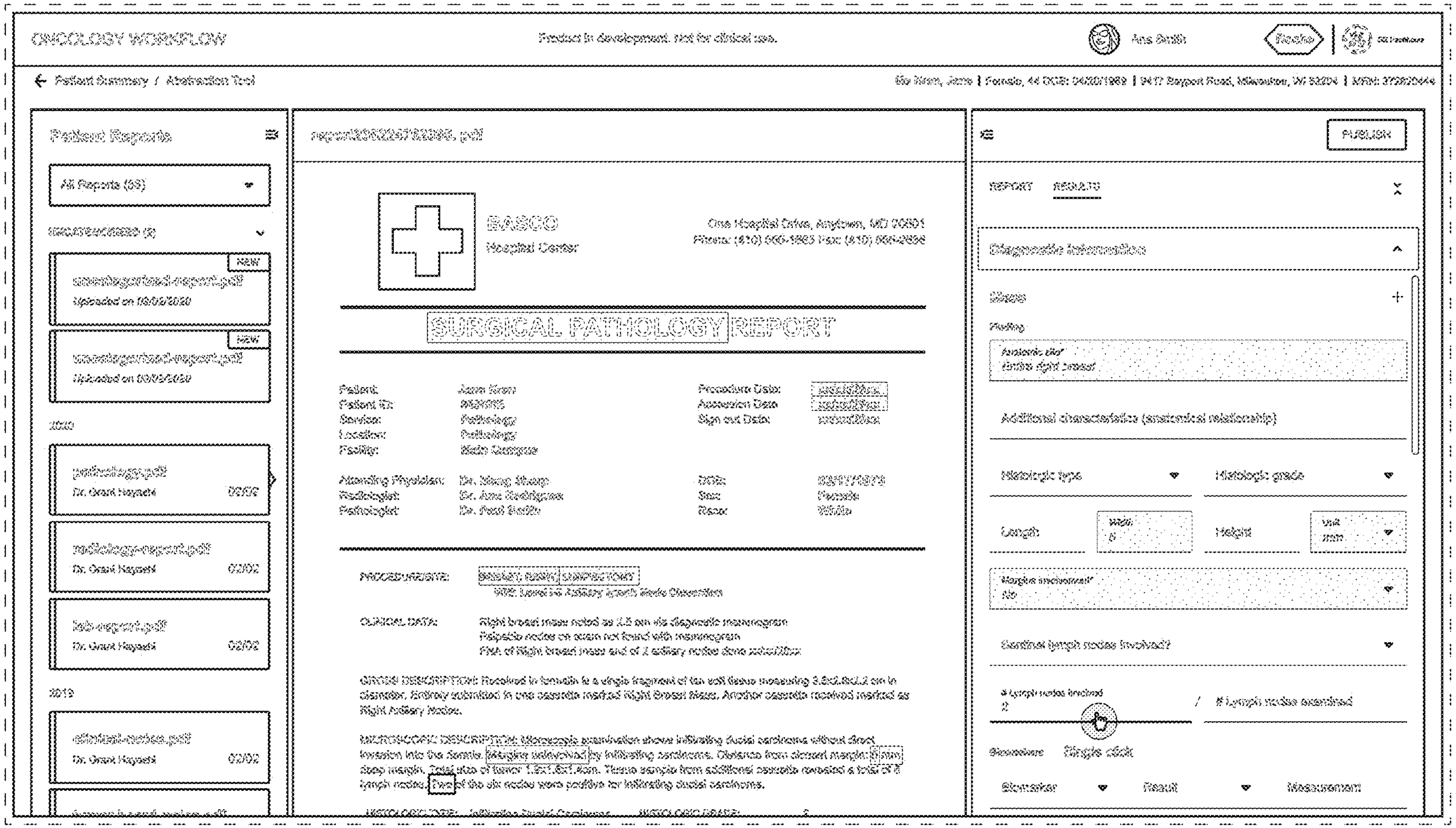
ONCOLOGY WORKFLOW
Product in development. Not for clinical use.
Ana Smith
Patient Summary / Abstraction Tool
Patient Reports
All Reports (53)
NEW
uncategorized-report.pdf
Uploaded on 10/03/2020
NEW
uncategorized-report.pdf
Uploaded on 09/03/2020
2020
pathology.pdf
Dr. Grant Hayashi 02/02
radiology-report.pdf
Dr. Grant Hayashi 02/02
lab-report.pdf
Dr. Grant Hayashi 02/02
2019
clinical-notes.pdf
Dr. Grant Hayashi 02/02
report20522257622884.pdf
BASCO
Hospital Center
One Hospital Drive, Anytown, MD 70801
SURGICAL PATHOLOGY REPORT
Patient: Jane Kren
Patient ID: 9834385
Service: Pathology
Location: Pathology
Facility: Main Campus
Procedure Date:
Accession Date
Sign out Date:
Attending Physician: Dr. Meng Sharp
Radiologist: Dr. Ana Rodriguez
Pathologist: Dr. Paul Smith
DOB:
Sex: Female
Race: White
PROCEDURE(S):
CLINICAL DATA:
GROSS DESCRIPTION:
MICROSCOPIC DESCRIPTION:
PUBLISH
REPORT
RESULTS
Diagnostic Information
Biopsy
Finding
Additional characteristics (anatomical relationship)
Histologic type
Histologic grade
Length
Height
Margin involvement?
Sentinel lymph nodes involved?
Lymph nodes involved
Lymph nodes examined
Biomarker
Single click
Biomarker
Result
Measurement

FIG. 5

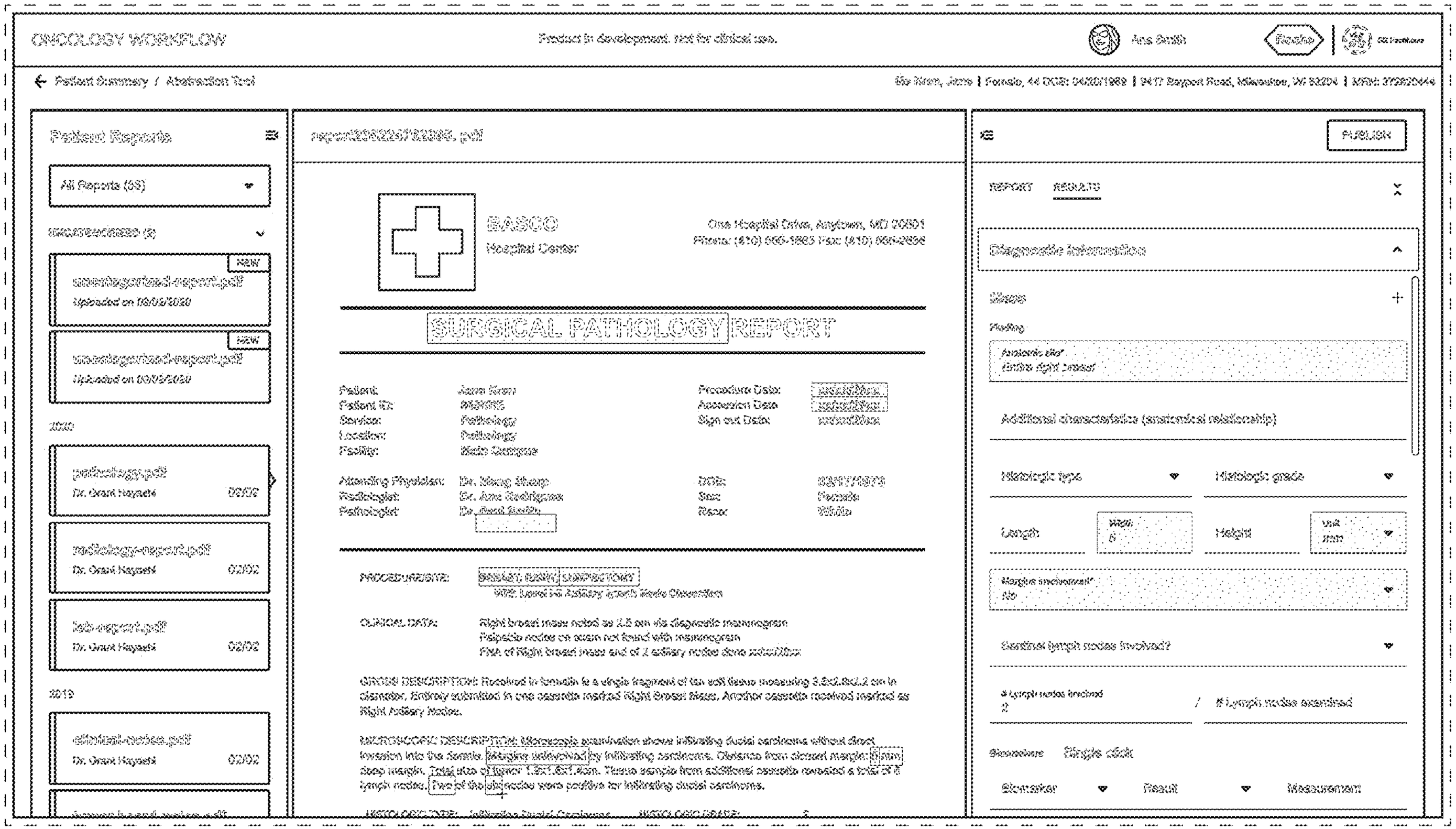
ONCOLOGY WORKFLOW
Product in development. Not for clinical use.
Ana Smith
Patient Summary / Abstraction Tool
Patient Reports
All Reports (53)
NEW
uncategorized-report.pdf
Uploaded on 10/03/2020
NEW
uncategorized-report.pdf
Uploaded on 09/03/2020
2020
pathology.pdf
Dr. Grant Hayashi 02/02
radiology-report.pdf
Dr. Grant Hayashi 02/02
lab-report.pdf
Dr. Grant Hayashi 02/02
2019
clinical-notes.pdf
Dr. Grant Hayashi 02/02
report20522257622884.pdf
BASCO
Hospital Center
One Hospital Drive, Anytown, MD 70801
SURGICAL PATHOLOGY REPORT
Patient: Jane Kren
Patient ID: 9824315
Service: Pathology
Location: Pathology
Facility: Main Campus
Procedure Date:
Accession Date:
Sign out Date:
Attending Physician: Dr. Meng Sharp
Radiologist: Dr. Ana Rodriguez
Pathologist: Dr. Grant Smith
DOB:
Sex: Female
Race: White
PROCEDURE(S):
CLINICAL DATA:
GROSS DESCRIPTION:
MICROSCOPIC DESCRIPTION:
PUBLISH
REPORT
RESULTS
Diagnostic Information
Biopsy
Finding
Additional characteristics (anatomical relationship)
Histologic type
Histologic grade
Length
Height
Unit
mm
Margins involved?
No
Sentinel lymph nodes involved?
Lymph nodes involved
2
Lymph nodes examined
Biomarker
Single click
Biomarker
Result
Measurement

FIG. 6

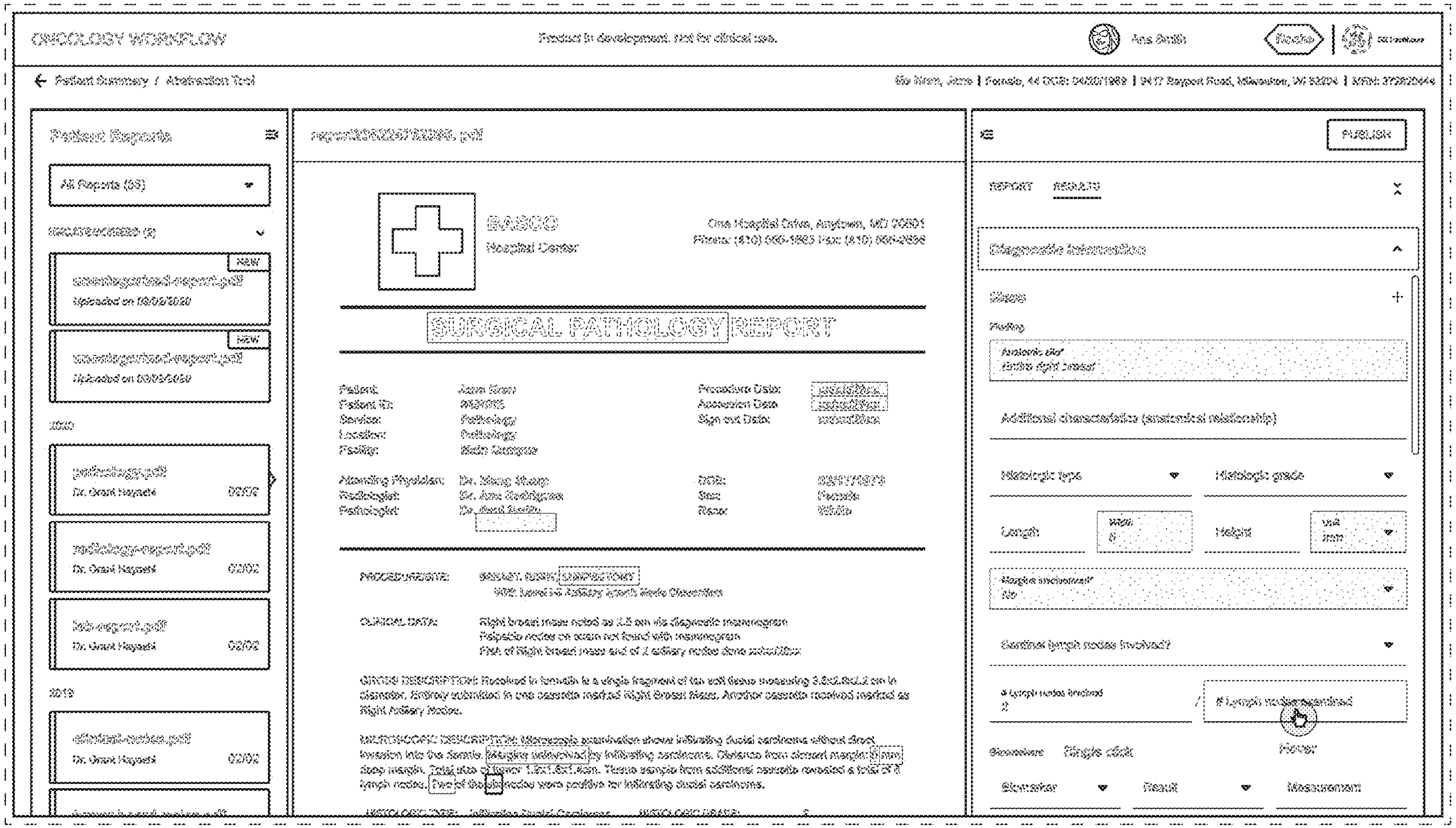
ONCOLOGY WORKFLOW
Product in development. Not for clinical use.
Ana Smith
Patient Summary / Abstraction Tool
Patient Reports
All Reports (53)
NEW
NEW
2020
pathology.pdf
Dr. Grant Hayashi 02/02
radiology-report.pdf
Dr. Grant Hayashi 02/02
lab-report.pdf
Dr. Grant Hayashi 02/02
2019
clinical-notes.pdf
Dr. Grant Hayashi 02/02
BASCO
Hospital Center
One Hospital Drive, Anytown, MD 70801
SURGICAL PATHOLOGY REPORT
Patient:
Patient ID:
Service:
Location:
Facility:
Pathology
Pathology
Main Campus
Procedure Date:
Accession Date
Sign out Date:
Attending Physician:
Radiologist:
Pathologist:
Dr. Mary Sharp
Dr. Ana Rodriguez
DOB:
Sex:
Race:
Female
White
PROCEDURE(S):
CLINICAL DATA:
Right breast mass noted as 4.5 cm via diagnostic mammogram
Palpable nodes on exam not found with mammogram
FNA of Right breast mass and of 2 axillary nodes done
GROSS DESCRIPTION: Received in formalin is a single fragment of fan soft tissue measuring
in diameter. Entirely submitted in one cassette marked Right Breast Mass. Another cassette received marked as Right Axillary Nodes.
MICROSCOPIC DESCRIPTION: Microscopic examination shows infiltrating ductal carcinoma without direct invasion into the dermis. Margins uninvolved by infiltrating carcinoma. Distance from closest margin: mm; deep margin. Total size of tumor x x cm. Tissue sample from additional cassette revealed a total of 6 lymph nodes. Two of the six nodes were positive for infiltrating ductal carcinoma.
PUBLISH
REPORT
RESULTS
Diagnostic Information
Biopsy
Finding
Additional characteristics (anatomical relationship)
Histologic type
Histologic grade
Length
Height
Sentinel lymph nodes involved?
Lymph nodes involved
2
Lymph nodes examined
Single click
Hover
Biomarker
Result
Measurement

FIG. 7

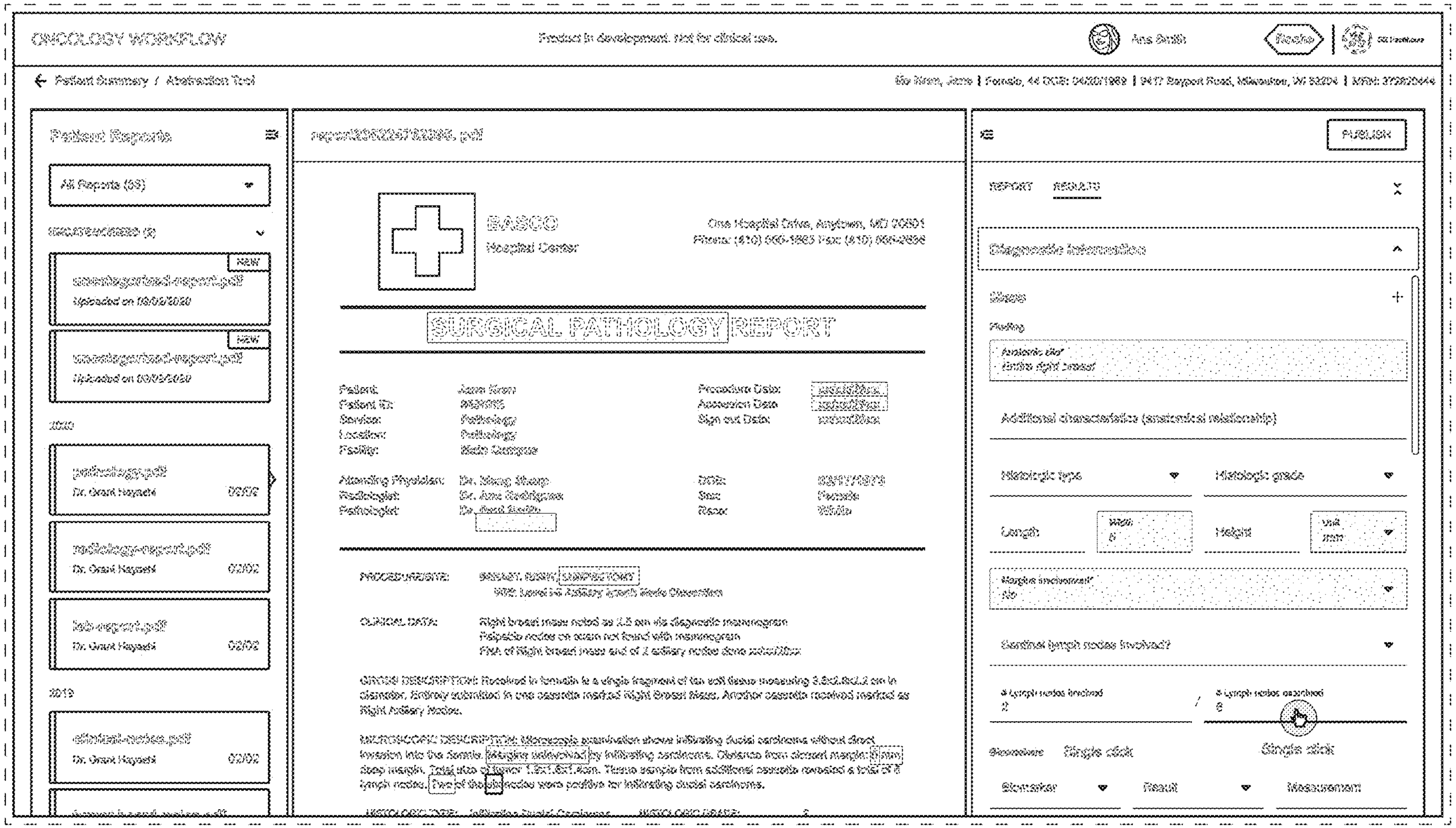
ONCOLOGY WORKFLOW
Product in development. Not for clinical use.
Ana Smith
Patient Summary / Abstraction Tool
Patient Reports
All Reports (53)
NEW
NEW
2020
pathology.pdf
Dr. Grant Hayashi 02/02
radiology-report.pdf
Dr. Grant Hayashi 02/02
lab-report.pdf
Dr. Grant Hayashi 02/02
2019
clinical-notes.pdf
Dr. Grant Hayashi 02/02
BASCO
Hospital Center
One Hospital Drive, Anytown, MD 70801
SURGICAL PATHOLOGY REPORT
Patient:
Patient ID:
Service:
Location:
Facility:
Pathology
Pathology
Main Campus
Attending Physician:
Radiologist:
Pathologist:
Dr. Mary Sharp
Dr. Ana Rodriguez
Procedure Date:
Accession Date
Sign out Date:
DOB:
Sex:
Race:
Female
White
PROCEDURE(S):
CLINICAL DATA:
PUBLISH
REPORT
RESULTS
Diagnostic Information
Blocks
Finding
Additional characteristics (anatomical relationship)
Histologic type
Histologic grade
Length
Height
Margins involvement?
Sentinel lymph nodes involved?
Lymph nodes involved
Lymph nodes examined
Single click
Single click
Biomarker
Result
Measurement

FIG. 8

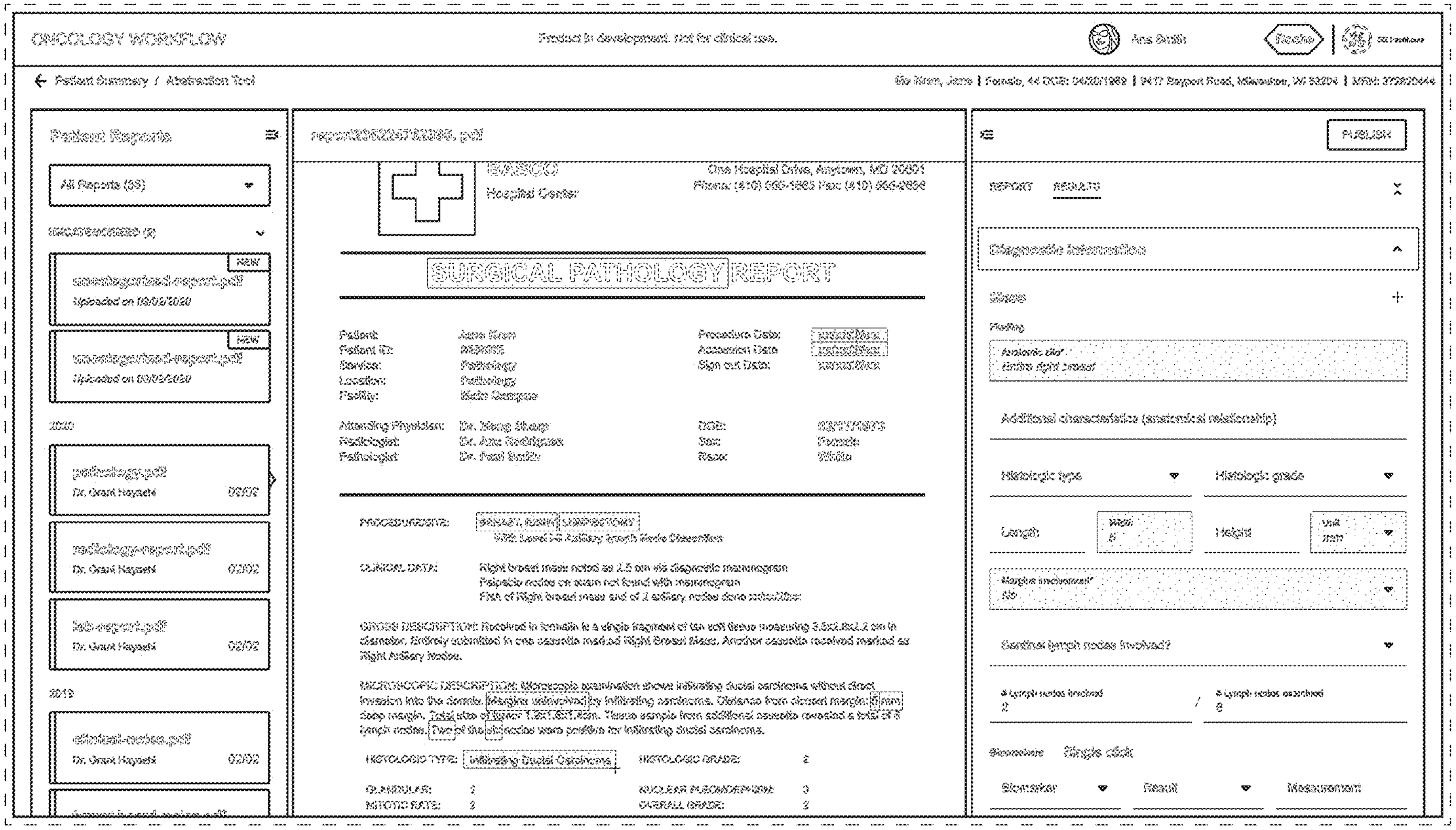
ONCOLOGY WORKFLOW
Product in development. Not for clinical use.
Ana Smith
Patient Summary / Abstraction Tool
Patient Reports
All Reports (53)
NEW
uncategorized-report.pdf
Uploaded on 10/03/2020
NEW
uncategorized-report.pdf
Uploaded on 10/03/2020
2020
pathology.pdf
Dr. Grant Hayashi 02/02
radiology-report.pdf
Dr. Grant Hayashi 02/02
lab-report.pdf
Dr. Grant Hayashi 02/02
2019
sentinel-nodes.pdf
Dr. Grant Hayashi 02/02
report20302257622884.pdf
BASCO
Hospital Center
SURGICAL PATHOLOGY REPORT
Patient: Jane Kron
Patient ID: 8829385
Service: Pathology
Location: Pathology
Facility: Main Campus
Procedure Date:
Accession Date:
Sign out Date:
Attending Physician: Dr. Meng Sharp
Radiologist: Dr. Ana Rodriguez
Pathologist: Dr. Paul Smith
DOB:
Sex: Female
Race: White
PROCEDURE(S):
CLINICAL DATA:
GROSS DESCRIPTION:
MICROSCOPIC DESCRIPTION:
HISTOLOGIC TYPE: Infiltrating Ductal Carcinoma
HISTOLOGIC GRADE:
TUBULES:
NUCLEAR PLEOMORPHISM:
MITOTIC RATE:
OVERALL GRADE:
PUBLISH
REPORT
RESULTS
Diagnostic Information
Biopsy
Finding
Additional characteristics (anatomical relationship)
Histologic type
Histologic grade
Length
Height
Margins involved?
Sentinel lymph nodes involved?
Lymph nodes involved
Lymph nodes examined
Biomarkers
Single click
Biomarker
Result
Measurement

FIG. 9

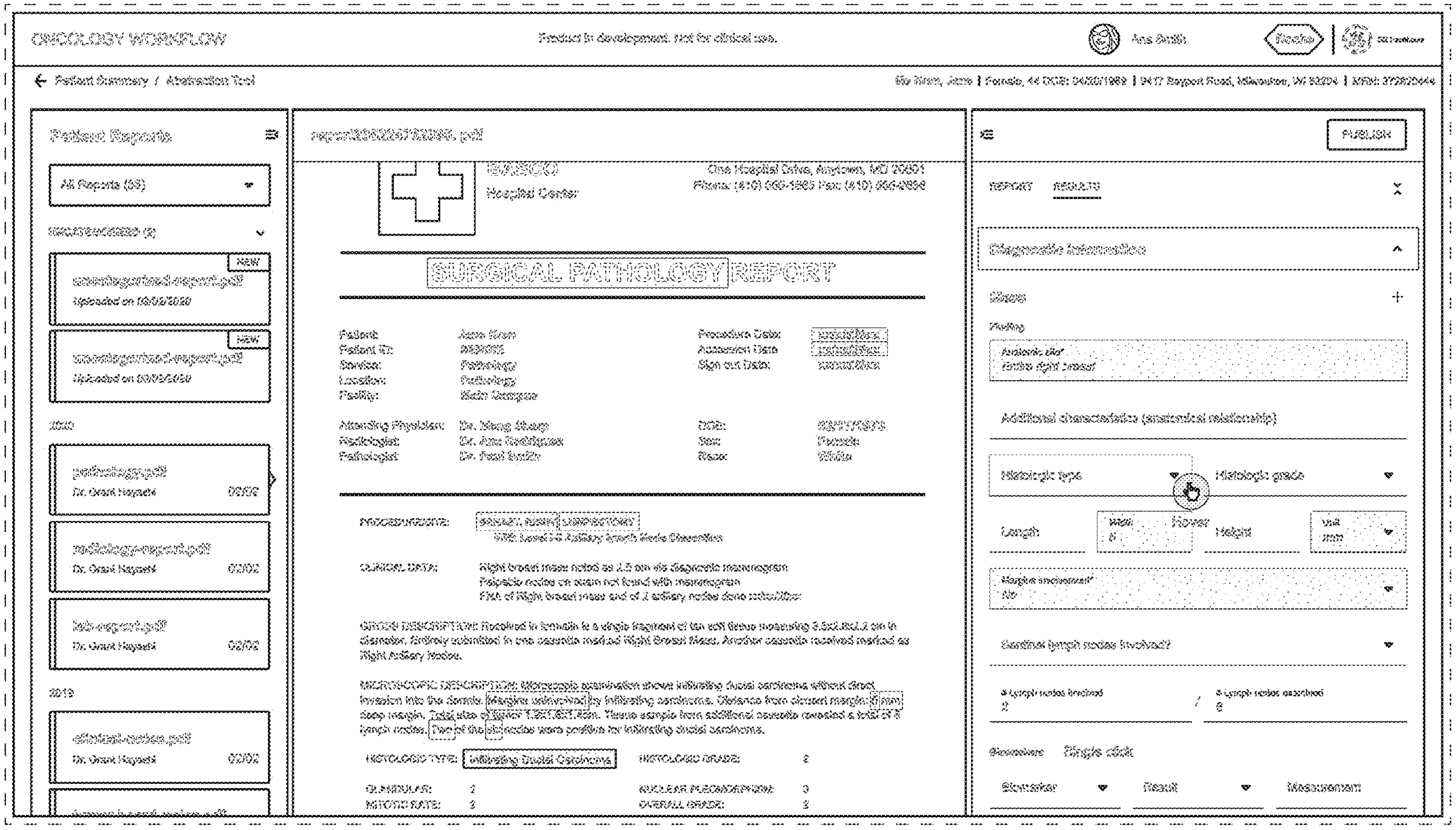
ONCOLOGY WORKFLOW
Product in development. Not for clinical use.
Ana Smith
Patient Summary / Abstraction Tool
Patient Reports
All Reports (53)
NEW
uncategorized-report.pdf
Uploaded on 10/03/2020
NEW
uncategorized-report.pdf
Uploaded on 10/03/2020
2020
pathology.pdf
Dr. Grant Hayashi 02/02
radiology-report.pdf
Dr. Grant Hayashi 02/02
lab-report.pdf
Dr. Grant Hayashi 02/02
2019
sentinel-nodes.pdf
Dr. Grant Hayashi 02/02
report20302257622864.pdf
BASCO
Hospital Center
SURGICAL PATHOLOGY REPORT
Patient: Jane Kron
Patient ID: 8829385
Service: Pathology
Location: Pathology
Facility: Main Campus
Procedure Date:
Accession Date:
Sign out Date:
Attending Physician: Dr. Meng Sharp
Radiologist: Dr. Ana Rodriguez
Pathologist: Dr. Paul Smith
DOB:
Sex: Female
Race: White
PROCEDURE(S):
CLINICAL DATA:
GROSS DESCRIPTION:
MICROSCOPIC DESCRIPTION:
HISTOLOGIC TYPE: Infiltrating Ductal Carcinoma
HISTOLOGIC GRADE:
GLANDULAR:
NUCLEAR PLEOMORPHISM:
MITOTIC RATE:
OVERALL GRADE:
PUBLISH
REPORT
RESULTS
Diagnostic Information
Blocks
Finding
Additional characteristics (anatomical relationship)
Histologic type
Histologic grade
Length
Width
Height
Margins involved?
Sentinel lymph nodes involved?
Lymph nodes involved
Lymph nodes examined
Biomarkers
Single click
Biomarker
Result
Measurement

FIG. 10

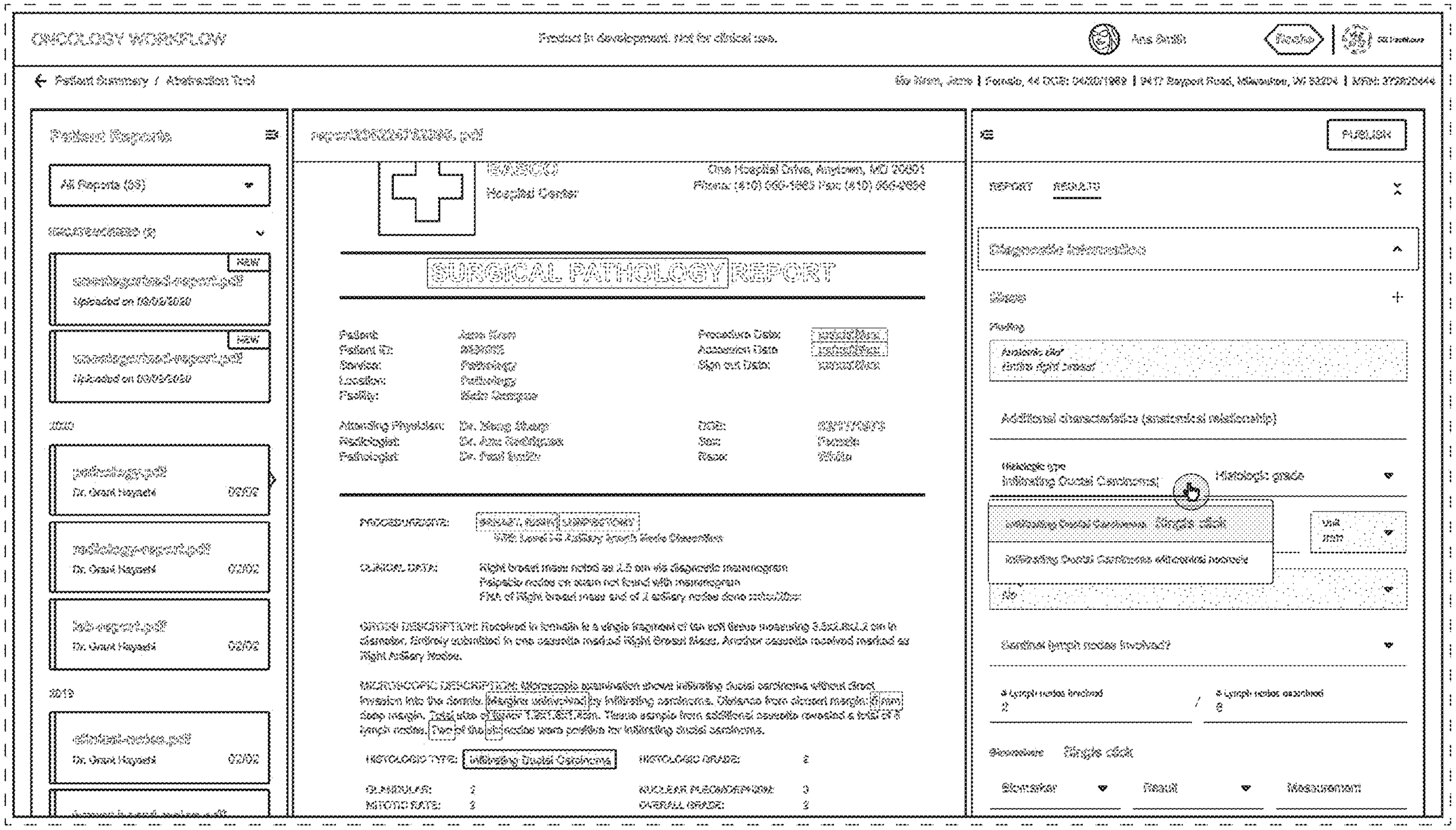
ONCOLOGY WORKFLOW
Product in development. Not for clinical use.
Ana Smith
Patient Summary / Abstraction Tool
Patient Reports
All Reports (53)
NEW
uncategorized-report.pdf
Uploaded on 10/03/2020
NEW
uncategorized-report.pdf
Uploaded on 10/03/2020
2020
pathology.pdf
Dr. Grant Hayashi 02/02
radiology-report.pdf
Dr. Grant Hayashi 02/02
lab-report.pdf
Dr. Grant Hayashi 02/02
2019
sentinel-nodes.pdf
Dr. Grant Hayashi 02/02
report20302257622884.pdf
BASCO
Hospital Center
SURGICAL PATHOLOGY REPORT
Patient: Jane Kron
Patient ID:
Service: Pathology
Location: Pathology
Facility: Main Campus
Procedure Date:
Accession Date
Sign out Date:
Attending Physician: Dr. Meng Sharp
Radiologist: Dr. Ana Rodriguez
Pathologist: Dr. Paul Smith
DOB:
Sex: Female
Race: White
PROCEDURE(S):
CLINICAL DATA:
GROSS DESCRIPTION:
MICROSCOPIC DESCRIPTION:
HISTOLOGIC TYPE: Infiltrating Ductal Carcinoma
HISTOLOGIC GRADE:
GLANDULAR:
MITOTIC RATE:
NUCLEAR PLEOMORPHISM:
OVERALL GRADE:
PUBLISH
REPORT
RESULTS
Diagnostic Information
Biopsy
Finding
Additional characteristics (anatomical relationship)
Histologic type
Infiltrating Ductal Carcinoma
Histologic grade
Infiltrating Ductal Carcinoma. Single click
Infiltrating Ductal Carcinoma with ductal necrosis
Sentinel lymph nodes involved?
Lymph nodes involved
Lymph nodes examined
Biomarkers
Single click
Biomarker
Result
Measurement

FIG. 11

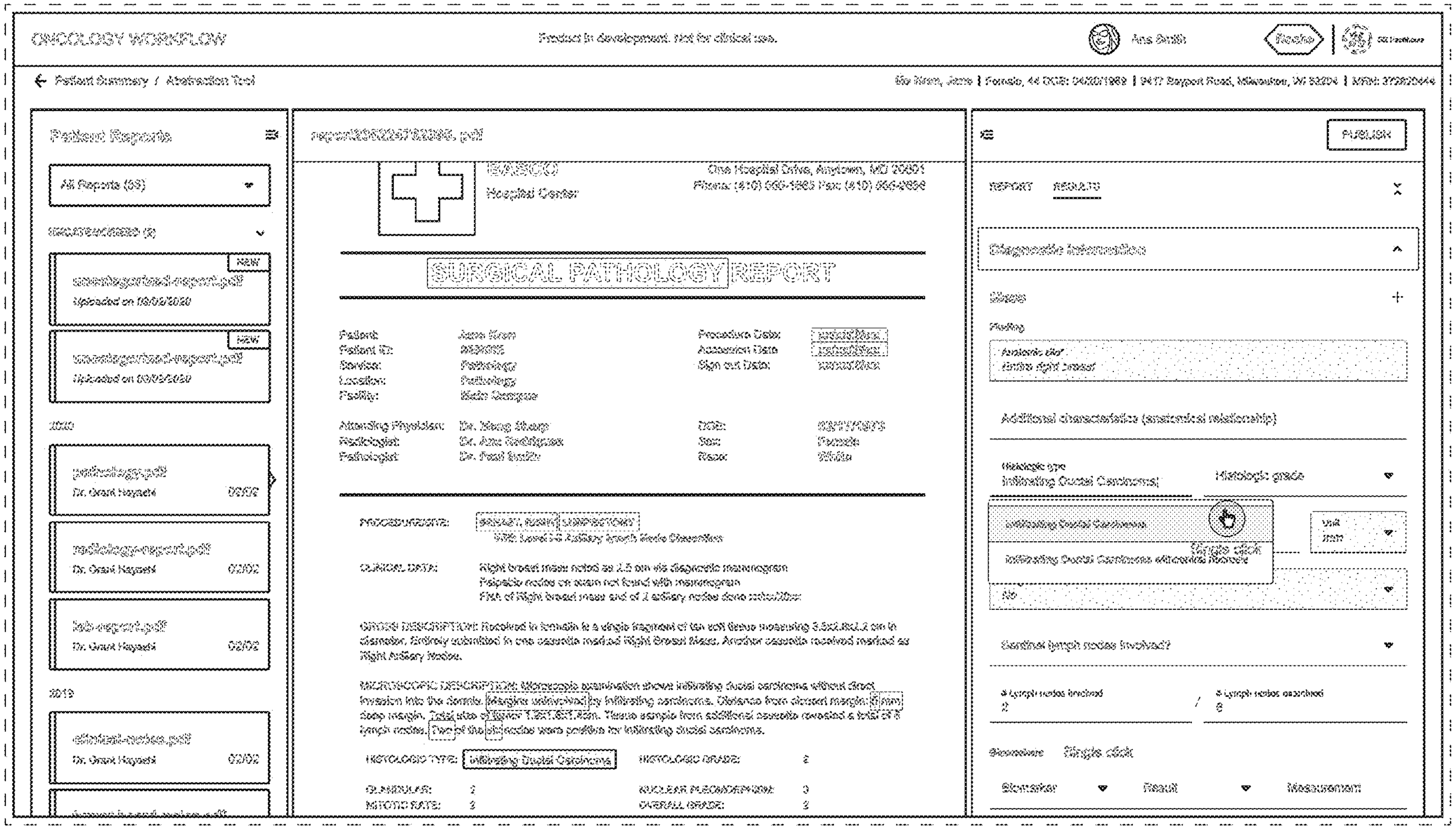
ONCOLOGY WORKFLOW
Product in development. Not for clinical use.
Ana Smith
Roche
Patient Summary / Abstraction Tool
Patient Reports
All Reports (53)
NEW
Uploaded on 10/03/2020
NEW
Uploaded on 10/03/2020
2020
pathology.pdf
Dr. Grant Hayashi 02/02
radiology-report.pdf
Dr. Grant Hayashi 02/02
lab-report.pdf
Dr. Grant Hayashi 02/02
2019
sentinel-nodes.pdf
Dr. Grant Hayashi 02/02
report20302257622884.pdf
BASCO
Hospital Center
One Hospital Drive, Anytown, MD 20801
SURGICAL PATHOLOGY REPORT
Patient: Jane Krom
Patient ID: 8829385
Service: Pathology
Location: Pathology
Facility: Main Campus
Procedure Date:
Accession Date:
Sign out Date:
Attending Physician: Dr. Meng Sharp
Radiologist: Dr. Ana Rodriguez
Pathologist: Dr. Paul Smith
DOB:
Sex: Female
Race: White
PROCEDURE(S):
CLINICAL DATA:
Right breast mass noted as 2.5 cm via diagnostic mammogram
Palpable nodes on exam not found with mammogram
Fish of Right breast mass and of 2 axillary nodes done concurrent
GROSS DESCRIPTION: Received in formalin is a single fragment of fat with tissue measuring
Right Axillary Nodes.
MICROSCOPIC DESCRIPTION: Microscopic examination shows infiltrating ductal carcinoma without direct invasion into the dermis.
HISTOLOGIC TYPE: Infiltrating Ductal Carcinoma
HISTOLOGIC GRADE:
TUBULES:
MITOTIC RATE:
NUCLEAR PLEOMORPHISM:
OVERALL GRADE:
PUBLISH
REPORT
RESULTS
Diagnostic Information
Biopsy
Finding
Anatomic site
Entire right breast
Additional characteristics (anatomical relationship)
Histologic type
Infiltrating Ductal Carcinoma
Histologic grade
Infiltrating Ductal Carcinoma
Single click
Infiltrating Ductal Carcinoma without Nodule
Sentinel lymph nodes involved?
Lymph nodes involved
2
Lymph nodes examined
6
Biomarkers
Single click
Biomarker
Result
Measurement

FIG. 12

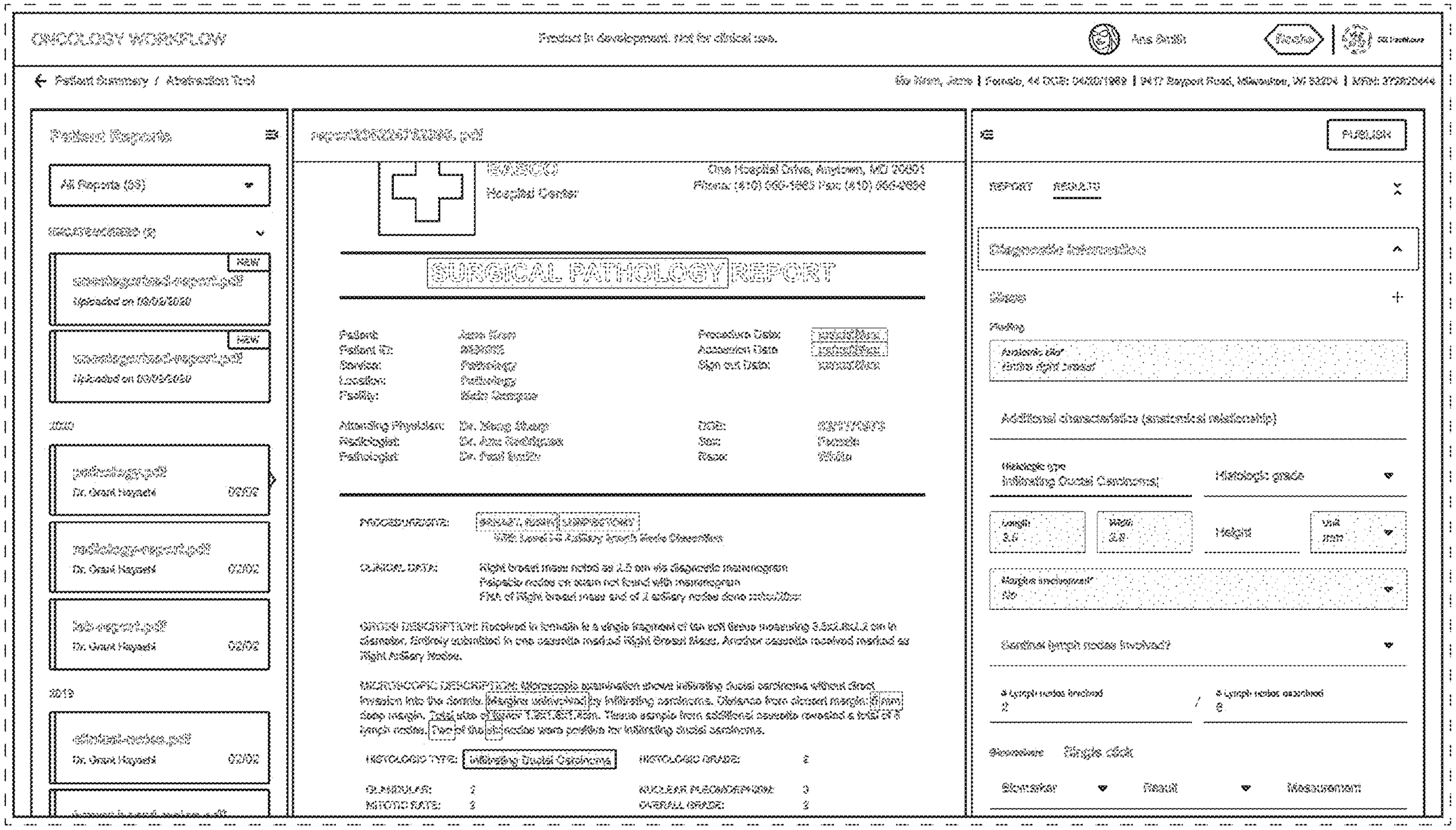
ONCOLOGY WORKFLOW
Product in development. Not for clinical use.
Ana Smith
Patient Summary / Abstraction Tool
Patient Reports
All Reports (53)
NEW
Uploaded on 10/03/2020
2020
pathology.pdf
Dr. Grant Hayashi 02/02
radiology-report.pdf
Dr. Grant Hayashi 02/02
lab-report.pdf
Dr. Grant Hayashi 02/02
2019
sentinel-nodes.pdf
Dr. Grant Hayashi 02/02
report20522257622884.pdf
BASCO
Hospital Center
One Hospital Drive, Anytown, MD 20801
SURGICAL PATHOLOGY REPORT
Patient:
Patient ID:
Service:
Location:
Facility:
Procedure Date:
Accession Date:
Sign out Date:
Attending Physician:
Radiologist:
Pathologist:
DOB:
Sex:
Race:
Female
White
PROCEDURE(S):
CLINICAL DATA:
GROSS DESCRIPTION:
MICROSCOPIC DESCRIPTION:
HISTOLOGIC TYPE:
Infiltrating Ductal Carcinoma
HISTOLOGIC GRADE:
TUBULES:
MITOTIC RATE:
NUCLEAR PLEOMORPHISM:
OVERALL GRADE:
PUBLISH
REPORT
RESULTS
Diagnostic Information
Blocks
Finding
Anatomic site*
Entire right breast
Additional characteristics (anatomical relationship)
Histologic type
Infiltrating Ductal Carcinoma
Histologic grade
Length
3.5
Width
2.8
Height
Unit
mm
Margins involved?*
No
Sentinel lymph nodes involved?
Lymph nodes involved
2
Lymph nodes examined
6
Biomarkers
Single click
Biomarker
Result
Measurement

FIG. 13

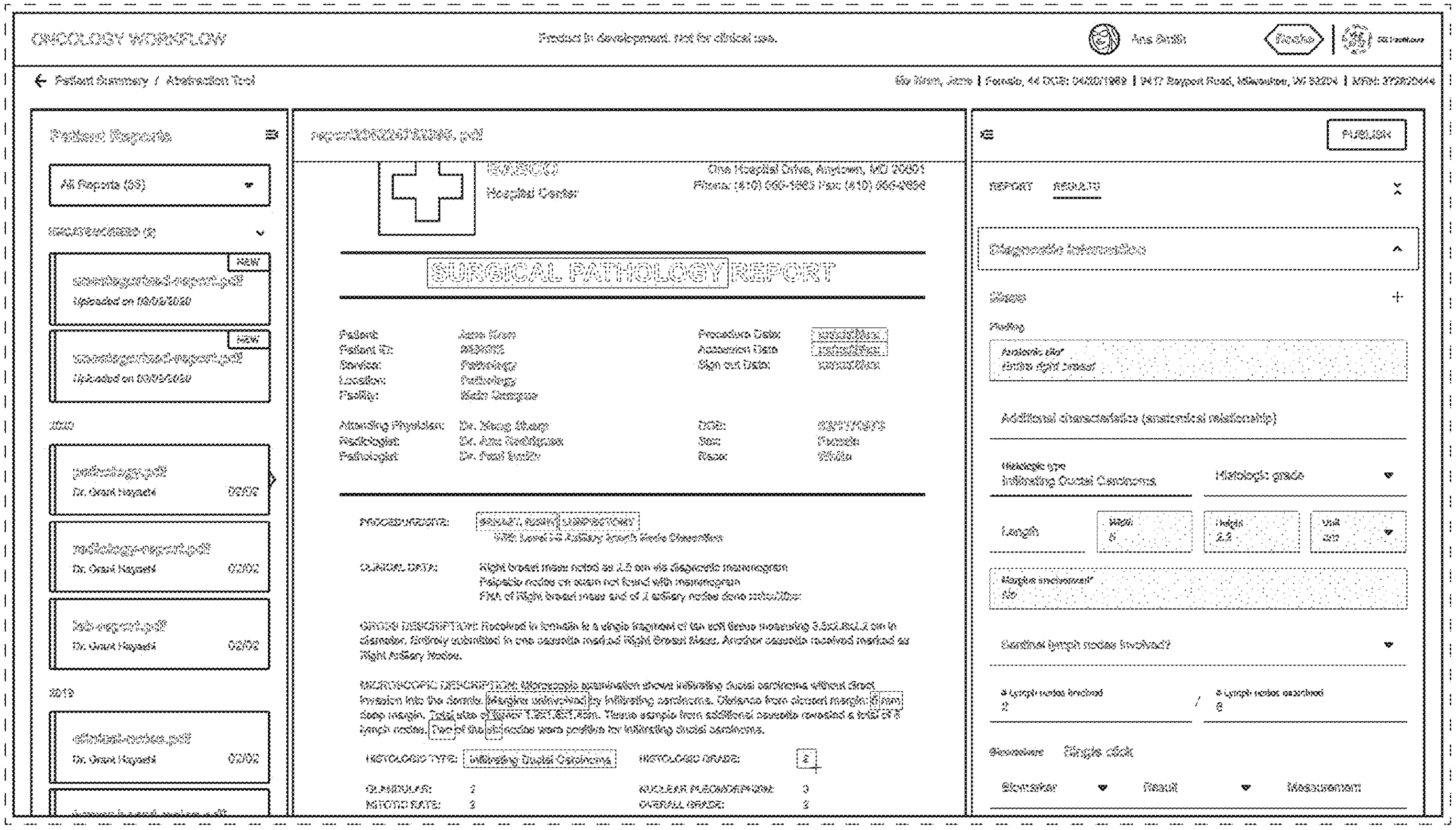
ONCOLOGY WORKFLOW
Product in development. Not for clinical use.
Ana Smith
Patient Summary / Abstraction Tool
Patient Reports
All Reports (53)
NEW
Uploaded on 10/03/2020
2020
pathology.pdf
Dr. Grant Hayashi 02/02
radiology-report.pdf
Dr. Grant Hayashi 02/02
lab-report.pdf
Dr. Grant Hayashi 02/02
2019
sentinel-nodes.pdf
Dr. Grant Hayashi 02/02
report20522257622884.pdf
BASCO
Hospital Center
One Hospital Drive, Anytown, MD 20601
SURGICAL PATHOLOGY REPORT
Patient: Jane Kron
Patient ID:
Service: Pathology
Location: Pathology
Facility: Main Campus
Procedure Date:
Accession Date
Sign out Date:
Attending Physician: Dr. Meng Sharp
Radiologist: Dr. Ana Rodriguez
Pathologist: Dr. Paul Smith
DOB:
Sex: Female
Race: White
PROCEDURE(S):
CLINICAL DATA:
Right breast mass noted as 2.5 cm via diagnostic mammogram
Palpable nodes on exam not found with mammogram
Fish of Right breast mass and of 2 axillary nodes done concurrent
GROSS DESCRIPTION: Received in formalin is a single fragment of fat with tissue measuring
in diameter. Entirely submitted in one cassette marked Right Breast Mass. Another cassette received marked as Right Axillary Nodes.
MICROSCOPIC DESCRIPTION: Microscopic examination shows infiltrating ductal carcinoma without direct invasion into the dermis. Margins uninvolved by infiltrating carcinoma. Distance from closest margin: mm; deep margin. Total size of tumor mm. Tissue sample from additional cassette revealed a total of 6 lymph nodes. Two of the six nodes were positive for infiltrating ductal carcinoma.
HISTOLOGIC TYPE: Infiltrating Ductal Carcinoma
HISTOLOGIC GRADE: 2
GLANDULAR: 2
MITOTIC RATE: 2
NUCLEAR PLEOMORPHISM: 3
OVERALL GRADE: 2
PUBLISH
REPORT
RESULTS
Diagnostic Information
Biopsy
Finding
Anatomic site*
Entire right breast
Additional characteristics (anatomical relationship)
Histologic type
Infiltrating Ductal Carcinoma
Histologic grade
Length
Width
6
Height
2.2
Unit
cm
Margins involved?*
No
Sentinel lymph nodes involved?
Lymph nodes involved
2
Lymph nodes examined
6
Biomarkers
Single click
Biomarker
Result
Measurement

FIG. 14

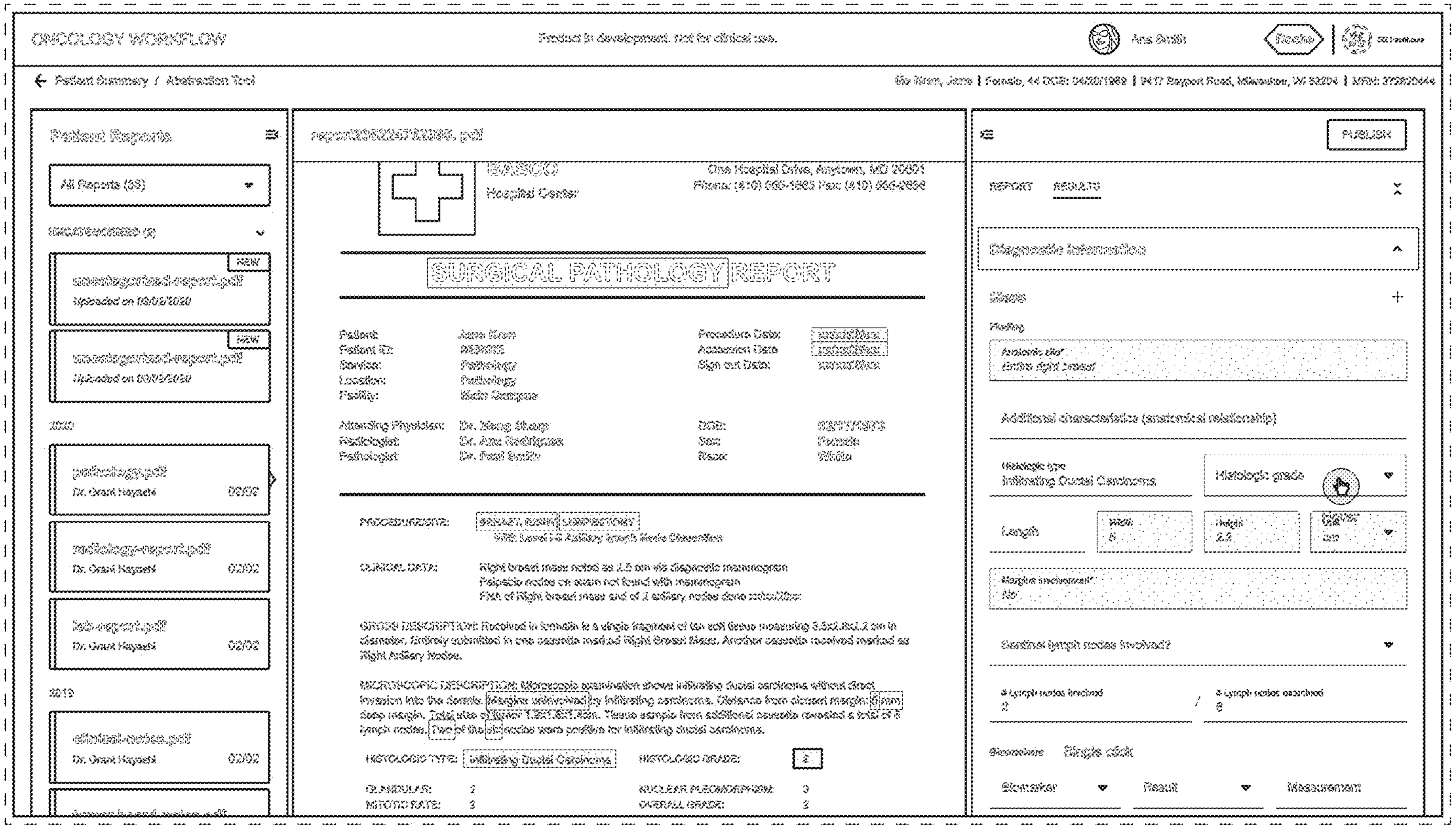
ONCOLOGY WORKFLOW
Product in development. Not for clinical use.
Ana Smith
Patient Summary / Abstraction Tool
Patient Reports
All Reports (53)
NEW
Uploaded on 10/02/2020
2020
pathology.pdf
Dr. Grant Hayashi 02/02
radiology-report.pdf
Dr. Grant Hayashi 02/02
lab-report.pdf
Dr. Grant Hayashi 02/02
2019
SURGICAL PATHOLOGY REPORT
Hospital Center
Patient:
Patient ID:
Service:
Location:
Facility:
Attending Physician:
Radiologist:
Pathologist:
Procedure Date:
Accession Date
Sign out Date:
DOB:
Sex:
Race:
Female
White
CLINICAL DATA:
GROSS DESCRIPTION:
MICROSCOPIC DESCRIPTION:
HISTOLOGIC TYPE:
Infiltrating Ductal Carcinoma
HISTOLOGIC GRADE:
GLANDULAR:
MITOTIC RATE:
NUCLEAR PLEOMORPHISM:
OVERALL GRADE:
PUBLISH
REPORT
RESULTS
Diagnostic Information
Blocks
Finding
Additional characteristics (anatomical relationship)
Histologic type
Infiltrating Ductal Carcinoma
Histologic grade
Length
Width
Height
Margins involved?
No
Sentinel lymph nodes involved?
Lymph nodes involved
Lymph nodes examined
Biomarkers
Single click
Biomarker
Result
Measurement

FIG. 15

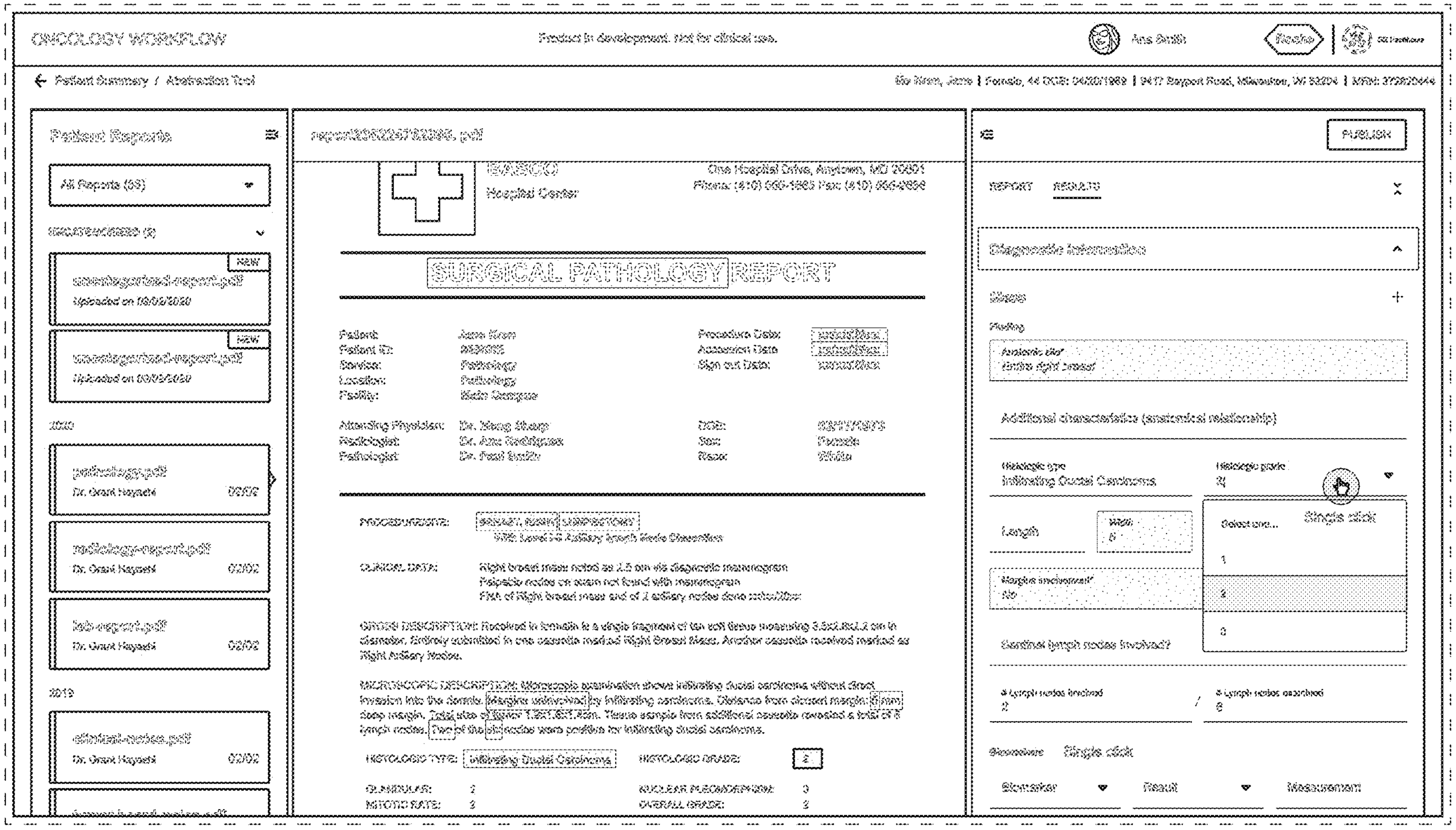
ONCOLOGY WORKFLOW
Product in development. Not for clinical use.
Ana Smith
Patient Summary / Abstraction Tool
Patient Reports
All Reports (53)
NEW
uncategorized-report.pdf
Uploaded on 10/03/2020
NEW
uncategorized-report.pdf
Uploaded on 10/03/2020
2020
pathology.pdf
Dr. Grant Hayashi 02/02
radiology-report.pdf
Dr. Grant Hayashi 02/02
lab-report.pdf
Dr. Grant Hayashi 02/02
2019
sentinel-nodes.pdf
Dr. Grant Hayashi 02/02
SURGICAL PATHOLOGY REPORT
Hospital Center
Patient:
Patient ID:
Service:
Location:
Facility:
Procedure Date:
Accession Date
Sign out Date:
Attending Physician:
Radiologist:
Pathologist:
DOB:
Sex:
Race:
Female
White
PROCEDURE(S):
CLINICAL DATA:
GROSS DESCRIPTION:
MICROSCOPIC DESCRIPTION:
HISTOLOGIC TYPE:
Infiltrating Ductal Carcinoma
HISTOLOGIC GRADE:
TUBULES:
MITOTIC RATE:
NUCLEAR PLEOMORPHISM:
OVERALL GRADE:
PUBLISH
REPORT
RESULTS
Diagnostic Information
Biopsy
Finding
Additional characteristics (anatomical relationship)
Histologic type
Infiltrating Ductal Carcinoma
Histologic grade
Length
Width
Margins involved?
No
Sentinel lymph nodes involved?
Lymph nodes involved
Lymph nodes examined
Biomarkers
Single click
Biomarker
Result
Measurement

FIG. 16

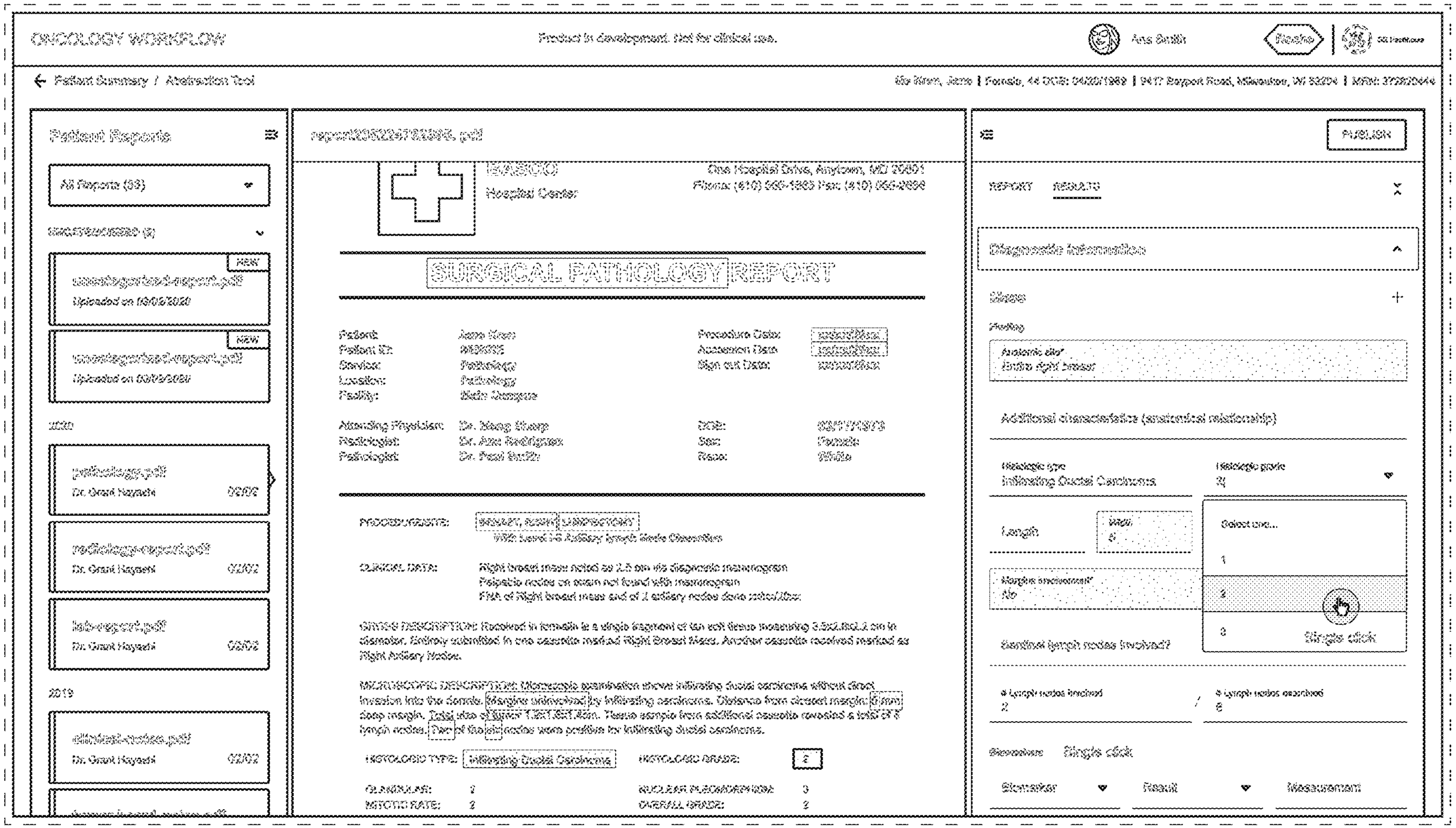
ONCOLOGY WORKFLOW
Product in development. Not for clinical use.
Ann Smith
Roche
Patient Summary / Abstraction Tool
Patient Reports
All Reports (33)
NEW
Uploaded on 10/05/2020
NEW
Uploaded on 10/05/2020
2020
pathology.pdf
Dr. Grant Hayashi
02/02
radiology-report.pdf
Dr. Grant Hayashi
02/02
lab-report.pdf
Dr. Grant Hayashi
02/02
2019
sentinel-notes.pdf
Dr. Grant Hayashi
02/02
report20502247023894.pdf
BASCO
Hospital Center
One Hospital Drive, Anytown, MD 20601
Phone: (410) 555-1365 Fax: (410) 555-2698
SURGICAL PATHOLOGY REPORT
Patient: Jane Kren
Patient ID: 9876543
Service: Pathology
Location: Pathology
Facility: Main Campus
Procedure Date:
Accession Date:
Sign out Date:
Attending Physician: Dr. Meng Sharp
Radiologist: Dr. Ana Rodriguez
Pathologist: Dr. Paul Smith
DOB:
Sex: Female
Race: White
PROCEDURE(S):
WITH Level I-II Axillary lymph Node Dissection
CLINICAL DATA:
Right breast mass noted on 2.5 cm via diagnostic mammogram
Palpable nodes on exam not found with mammogram
FNA of Right breast mass and of 2 axillary nodes done
GROSS DESCRIPTION: Received in formalin is a single fragment of fat and tissue measuring
in diameter. Entirely submitted in one cassette marked Right Breast Mass. Another cassette received marked as Right Axillary Nodes.
MICROSCOPIC DESCRIPTION: Microscopic examination shows infiltrating ductal carcinoma without direct invasion into the dermis. Margins unaffected by infiltrating carcinoma. Distance from closest margin:
deep margin.
lymph nodes.
HISTOLOGIC TYPE: Infiltrating Ductal Carcinoma
HISTOLOGIC GRADE:
GLANDULAR: 2
MITOTIC RATE: 2
NUCLEAR PLEOMORPHISM: 3
OVERALL GRADE: 2
PUBLISH
REPORT
RESULTS
Diagnostic Information
Biopsy
Finding
Anatomic site*
Entire right breast
Additional characteristics (anatomical relationship)
Histologic type
Infiltrating Ductal Carcinoma
Histologic grade
3
Length
Width
6
Select one...
1
2
3
Single click
Margins involved*
No
Sentinel lymph nodes involved?
Lymph nodes involved
2
Lymph nodes examined
6
Biomarkers
Single click
Biomarker
Result
Measurement

FIG. 17

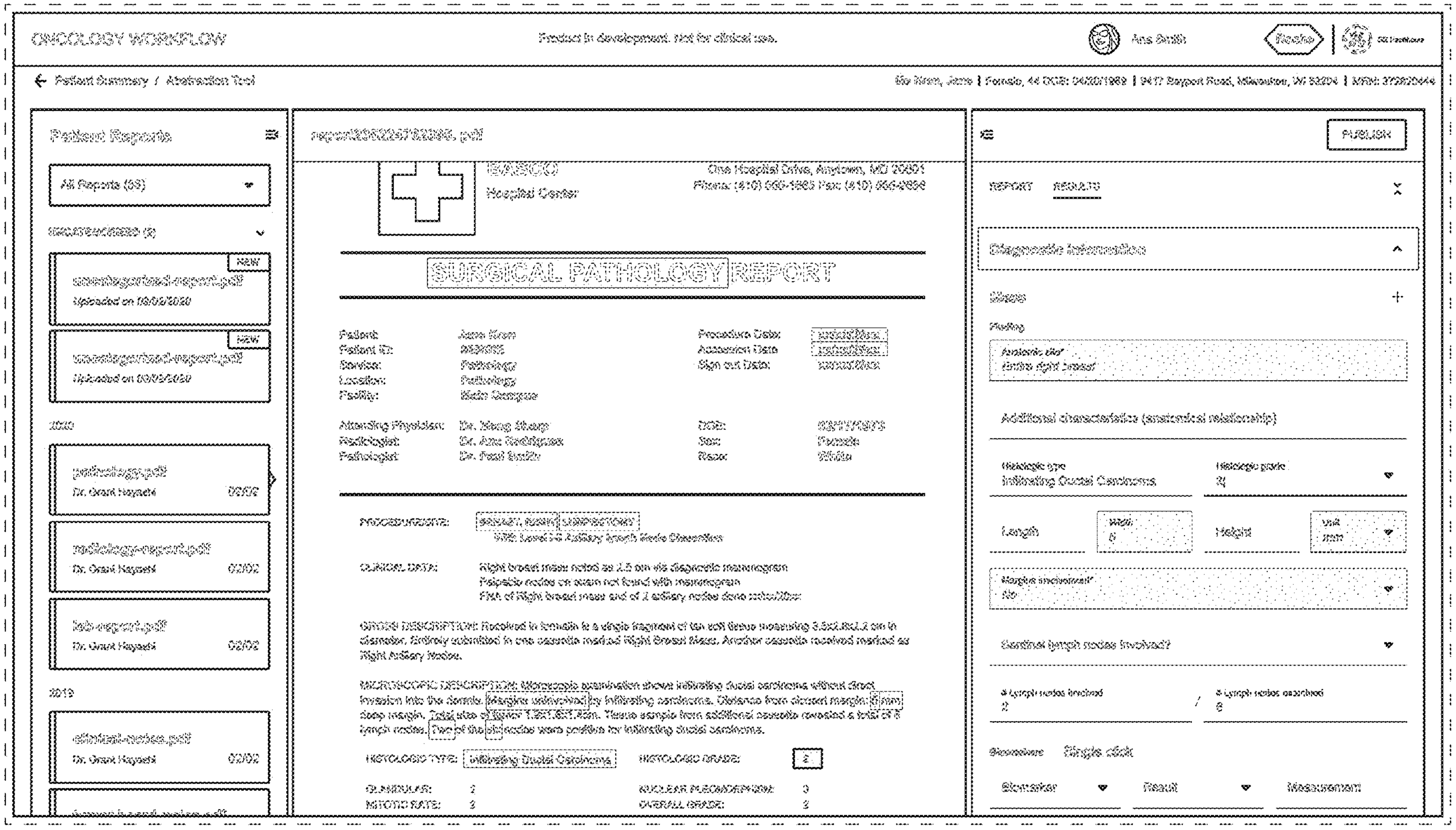
ONCOLOGY WORKFLOW
Product in development. Not for clinical use.
Ana Smith
Patient Summary / Abstraction Tool
Patient Reports
All Reports (53)
NEW
uncategorized-report.pdf
Uploaded on 10/03/2020
NEW
uncategorized-report.pdf
Uploaded on 10/03/2020
2020
pathology.pdf
Dr. Grant Hayashi 02/02
radiology-report.pdf
Dr. Grant Hayashi 02/02
lab-report.pdf
Dr. Grant Hayashi 02/02
2019
sentinel-nodes.pdf
Dr. Grant Hayashi 02/02
report20522257622864.pdf
BASCO
Hospital Center
One Hospital Drive, Anytown, MD 20601
SURGICAL PATHOLOGY REPORT
Patient: Jane Krom
Patient ID:
Service: Pathology
Location: Pathology
Facility: Main Campus
Procedure Date:
Accession Date
Sign out Date:
Attending Physician: Dr. Meng Sharp
Radiologist: Dr. Ana Rodriguez
Pathologist: Dr. Paul Smith
DOB:
Sex: Female
Race: White
PROCEDURE(S):
CLINICAL DATA:
GROSS DESCRIPTION:
MICROSCOPIC DESCRIPTION:
HISTOLOGIC TYPE: Infiltrating Ductal Carcinoma
HISTOLOGIC GRADE:
TUBULES:
MITOTIC RATE:
NUCLEAR PLEOMORPHISM:
OVERALL GRADE:
PUBLISH
REPORT
RESULTS
Diagnostic Information
Blocks
Finding
Anatomic site*
Entire right breast
Additional characteristics (anatomical relationship)
Histologic type
Infiltrating Ductal Carcinoma
Histologic grade
2
Length
Width
6
Height
Unit
mm
Margins involved?*
No
Sentinel lymph nodes involved?
Lymph nodes involved
2
Lymph nodes examined
6
Biomarkers
Single click
Biomarker
Result
Measurement

FIG. 18

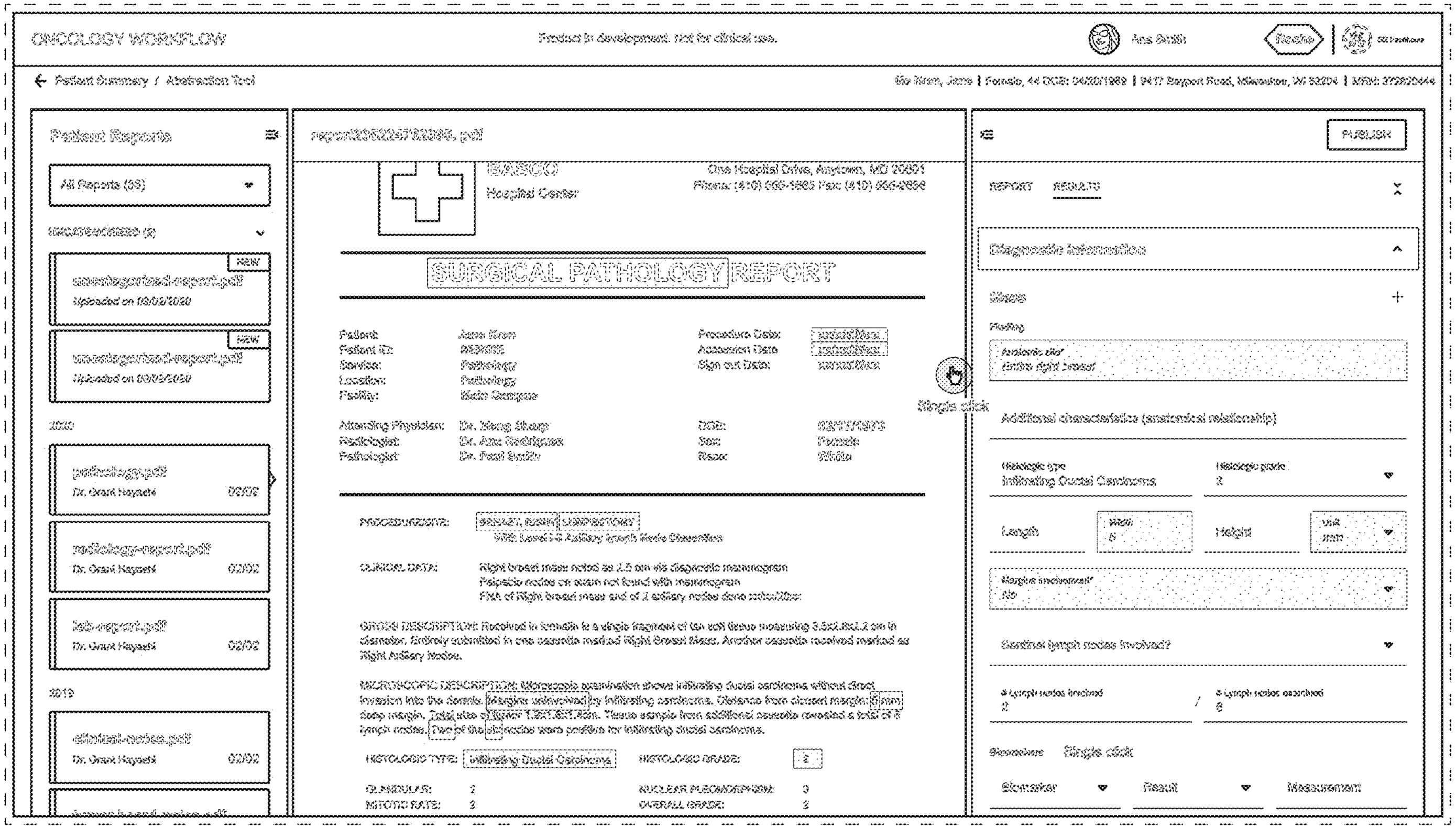
ONCOLOGY WORKFLOW
Product in development. Not for clinical use.
Patient Summary / Abstraction Tool
Patient Reports
All Reports (53)
NEW
pathology-report.pdf
Uploaded on 10/03/2020
NEW
pathology-report.pdf
Uploaded on 10/03/2020
2020
pathology.pdf
Dr. Grant Hayashi 02/02
radiology-report.pdf
Dr. Grant Hayashi 02/02
lab-report.pdf
Dr. Grant Hayashi 02/02
2019
clinical-notes.pdf
Dr. Grant Hayashi 02/02
report20522257622884.pdf
BASCO
Hospital Center
SURGICAL PATHOLOGY REPORT
Patient:
Patient ID:
Service:
Location:
Facility:
Attending Physician:
Radiologist:
Pathologist:
Procedure Date:
Accession Date
Sign out Date:
DOB:
Sex:
Race:
Single click
PUBLISH
REPORT
RESULTS
Diagnostic Information
Biopsy
Additional characteristics (anatomical relationship)
Histologic type
Infiltrating Ductal Carcinoma
Histologic grade
Length
Height
Sentinel lymph nodes involved?
Lymph nodes involved
Lymph nodes examined
Biomarker
Result
Measurement

FIG. 19