



US00D910673S

(12) **United States Design Patent** (10) **Patent No.:** **US D910,673 S**
Krishnamurthy et al. (45) **Date of Patent:** **** Feb. 16, 2021**

(54) **DISPLAY SCREEN WITH GRAPHICAL USER INTERFACE FOR A CLINICOGRAPH**

Primary Examiner — Christian P. McLean
(74) *Attorney, Agent, or Firm* — Hayes Soloway P.C.

(71) Applicant: **TATA CONSULTANCY SERVICES LIMITED**, Mumbai (IN)

(72) Inventors: **Girish Krishnamurthy**, Bengaluru (IN); **Sajeeli Goyle**, Bengaluru (IN); **Sanjay Tripathi**, Bengaluru (IN)

(57) **CLAIM**

We claim the ornamental design for a display screen with graphical user interface for a clinicograph, as shown and described.

(73) Assignee: **TATA CONSULTANCY SERVICES LIMITED**

(**) Term: **15 Years**

DESCRIPTION

(21) Appl. No.: **29/672,566**

FIG. 1 is a front view of a first image in a sequence for a display screen with graphical user interface for a clinicograph;

(22) Filed: **Dec. 6, 2018**

(51) **LOC (13) Cl.** **14-04**

(52) **U.S. Cl.**
USPC **D14/486**

(58) **Field of Classification Search**
USPC D14/485–495
CPC G06F 3/048; G06F 3/0481; G06F 3/04812; G06F 3/04817; G06F 3/0482; G06F 3/0483; G06F 3/0484; G06F 3/04847; G06F 3/0485; G06F 3/04855; G06F 3/04886; G06Q 30/00; H03J 1/00; H03J 1/0008; H03J 1/0016; H03J 1/0025; H04N 5/00; H04N 5/08; H04N 5/14; H04N 5/222; H04N 5/225; H04N 5/232; H04N 5/445; H04N 5/44543; H04N 5/45; H04N 2005/44517; H04N 2005/44521; H04N 2005/44526; H04N 2005/4453; H04N 2005/44534; H04N 2005/44539; H04N 2005/44547; H04N 2005/44556; H04N

FIG. 2 is a front view of a second image thereof; FIG. 3 is a front view of a third image thereof; FIG. 4 is a front view of a fourth image thereof; FIG. 5 is a front view of a fifth image thereof; FIG. 6 is a front view of a sixth image thereof; FIG. 7 is a front view of a seventh image thereof; FIG. 8 is a front view of an eighth image thereof; FIG. 9 is a front view of a ninth image thereof; FIG. 10 is a front view of a tenth image thereof; FIG. 11 is a front view of an eleventh image thereof; FIG. 12 is a front view of a twelfth image thereof; FIG. 13 is a front view of a thirteenth image thereof; FIG. 14 is a front view of a fourteenth image thereof; and, FIG. 15 is a front view of a fifteenth image thereof.

The outermost broken line rectangle illustrates a display screen and forms no part of the claimed design. The broken line showing of the hand illustrates environmental subject matter only and forms no part of the claimed design. The remaining broken lines illustrate portions of the graphical user interface that form no part of the claimed design. The appearance of the image transitions sequentially between the images shown in FIGS. 1-15, The process or period in which an image transitions to another image forms no part of the claimed design.

(Continued)


(56) **References Cited**

U.S. PATENT DOCUMENTS

D538,815 S * 3/2007 Noviello D14/485
D679,285 S * 4/2013 Stidsen D14/486

(Continued)

1 Claim, 15 Drawing Sheets



(58) **Field of Classification Search**

CPC 2005/4456; H04N 2005/44565; H04N
 2005/44569; H04N 2005/44573; H04N
 21/00; H04N 21/234; H04N 21/431;
 H04N 21/4312; H04N 21/4314; H04N
 21/4316

See application file for complete search history.

(56) **References Cited**

U.S. PATENT DOCUMENTS

D680,548 S * 4/2013 Goldstein D14/485
 D707,245 S * 6/2014 Bruck D14/486
 D751,085 S * 3/2016 Winther D14/485
 D776,136 S * 1/2017 Chen D14/485
 D779,502 S * 2/2017 Clapper D14/485
 D781,910 S * 3/2017 Day D14/488
 D786,899 S * 5/2017 Parmar D14/486
 D807,385 S * 1/2018 Olsen D14/486
 D822,047 S * 7/2018 Wills D14/486
 D823,327 S * 7/2018 Durkan D14/486
 D826,244 S * 8/2018 Yampolskaya D14/486
 D839,279 S * 1/2019 Dudey D14/485
 D846,577 S * 4/2019 Vazquez D14/486
 D853,420 S * 7/2019 Ambrose D14/486
 D877,768 S * 3/2020 Lirov D14/486
 D881,213 S * 4/2020 Zimmerman D14/486
 D882,598 S * 4/2020 Belliveau D14/485
 D892,831 S * 8/2020 Kim D14/486
 2010/0281383 A1* 11/2010 Meaney G11B 27/031
 715/723
 2013/0055131 A1* 2/2013 Leong G06F 3/0484
 715/770
 2017/0116373 A1* 4/2017 Ginsburg G06F 3/04817

* cited by examiner

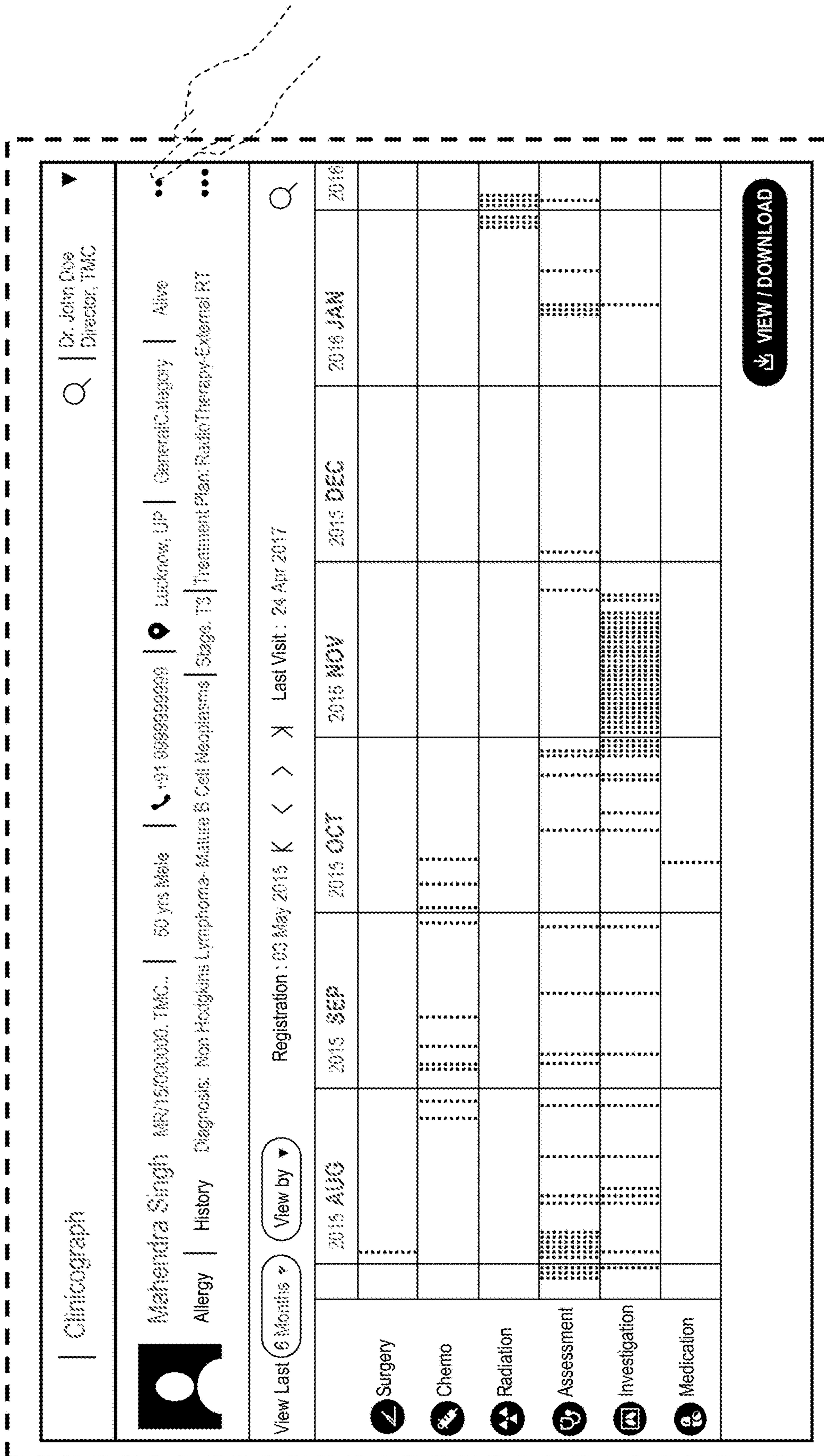




Fig. 1



Clinicograph

Dr. John Doe
Director, TMC



Mahendi
Allergy

View Last 6 Months

Demographics Close X

| | | | | | | |
|---------------------|---------------------------|-----------------------|-------------------|-----------------------|-----------------------|----------------------------------|
| Language English | Marital Status Married | Education Graduate | Religion Hindu | Occupation Officer | Blood Group B + VE | Registration Date 03 May 2015 |
|---------------------|---------------------------|-----------------------|-------------------|-----------------------|-----------------------|----------------------------------|

Identification

| | |
|----------------------|----------|
| Identification Type | Passport |
| Identification Value | ##### |
| Period Start | ##### |
| Period End | ##### |
| Additional Details | India |

Communication

Address

Patient Kin

| | | | | | |
|---------|-------|-----------|------------|---------------|------------|
| Surgery | Chemo | Radiation | Assessment | Investigation | Medication |
| ▶ | ▶ | ▶ | ▶ | ▶ | ▶ |

| | | | | | | |
|------|------|------|------|------|------|------|
| 2016 | 2015 | 2014 | 2013 | 2012 | 2011 | 2010 |
| JAN | FEB | MAR | APR | MAY | JUN | JUL |

Active

VIEW / DOWNLOAD

Fig. 2

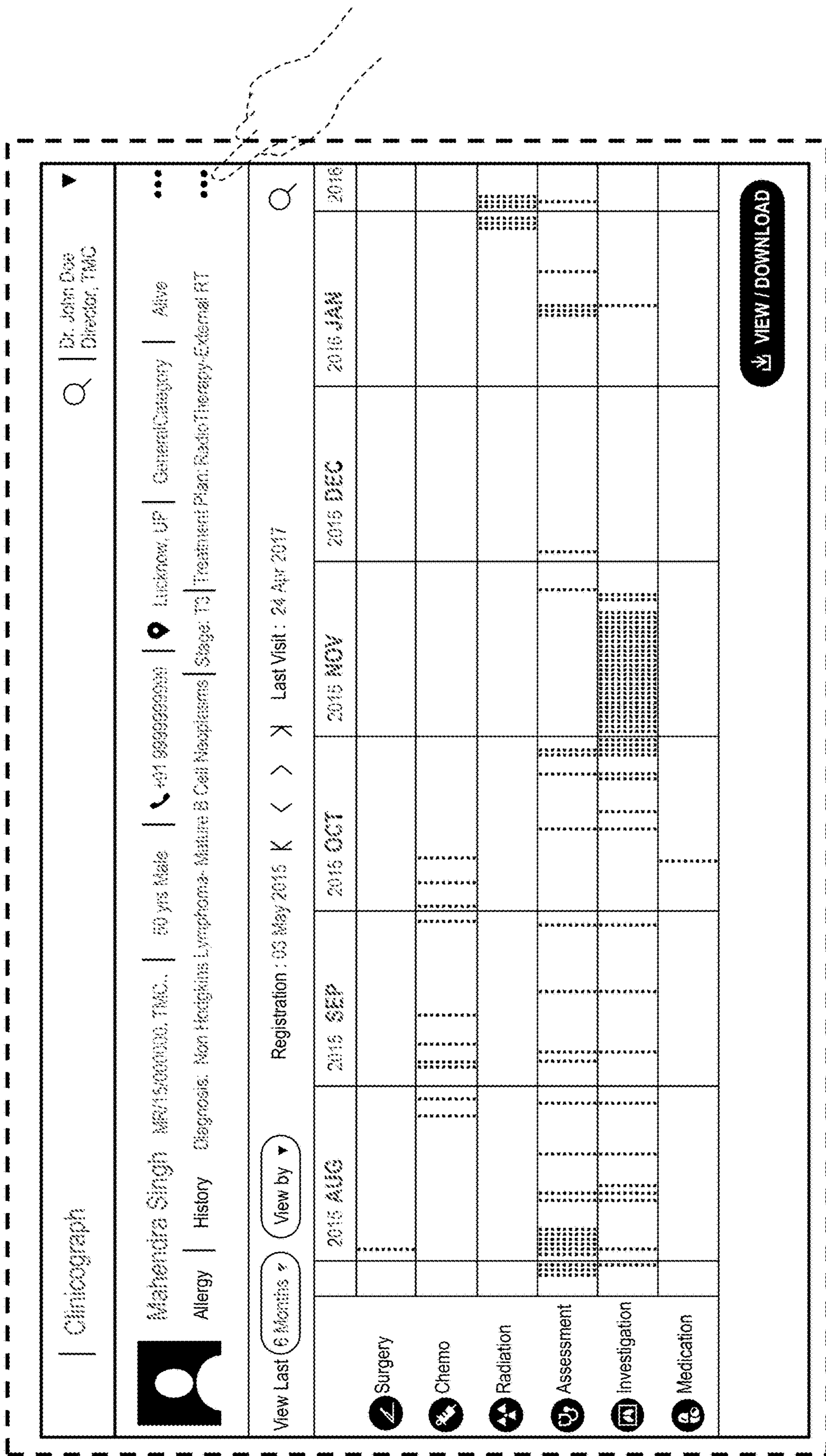


Fig. 3

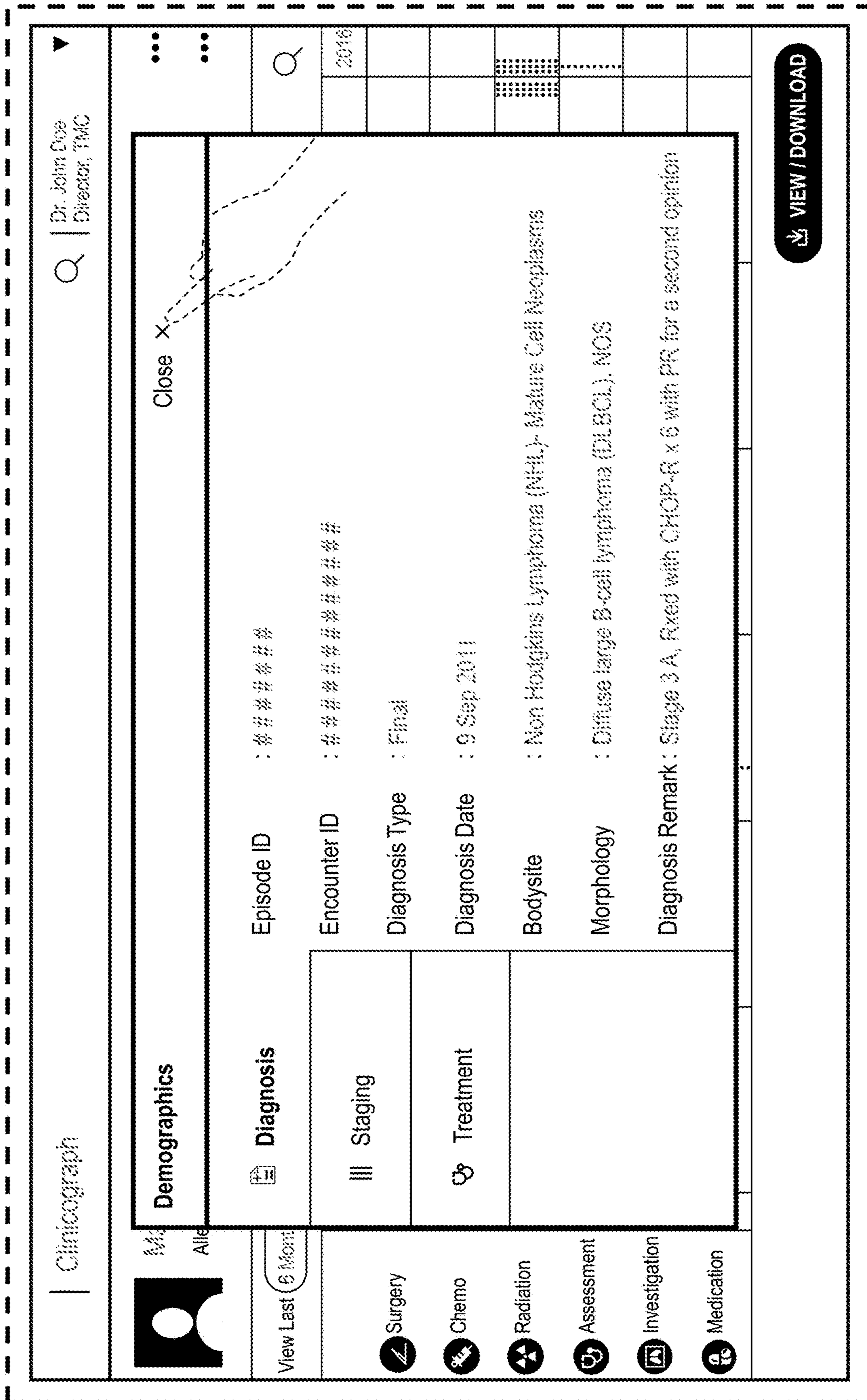


Fig. 4

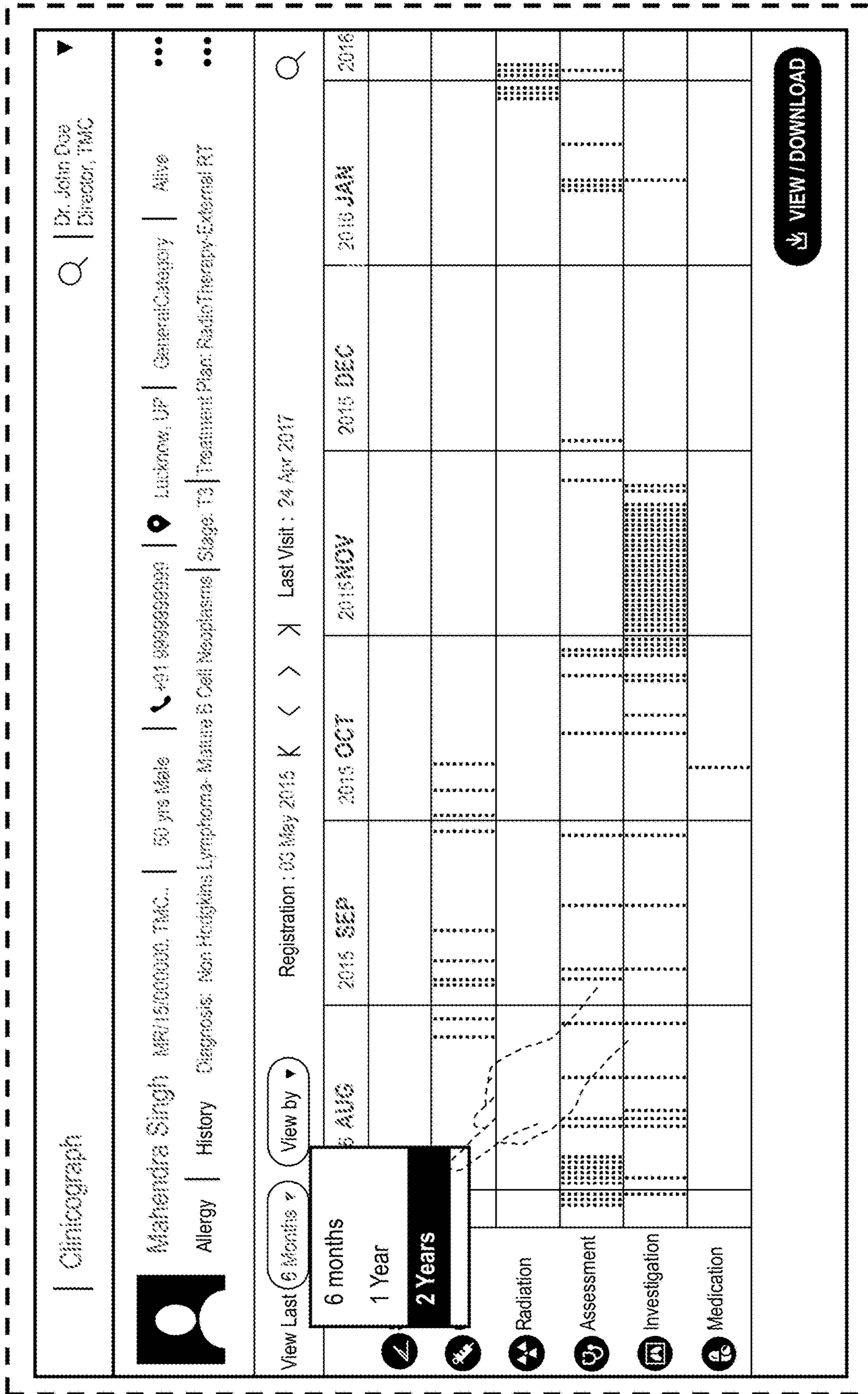


Fig. 5

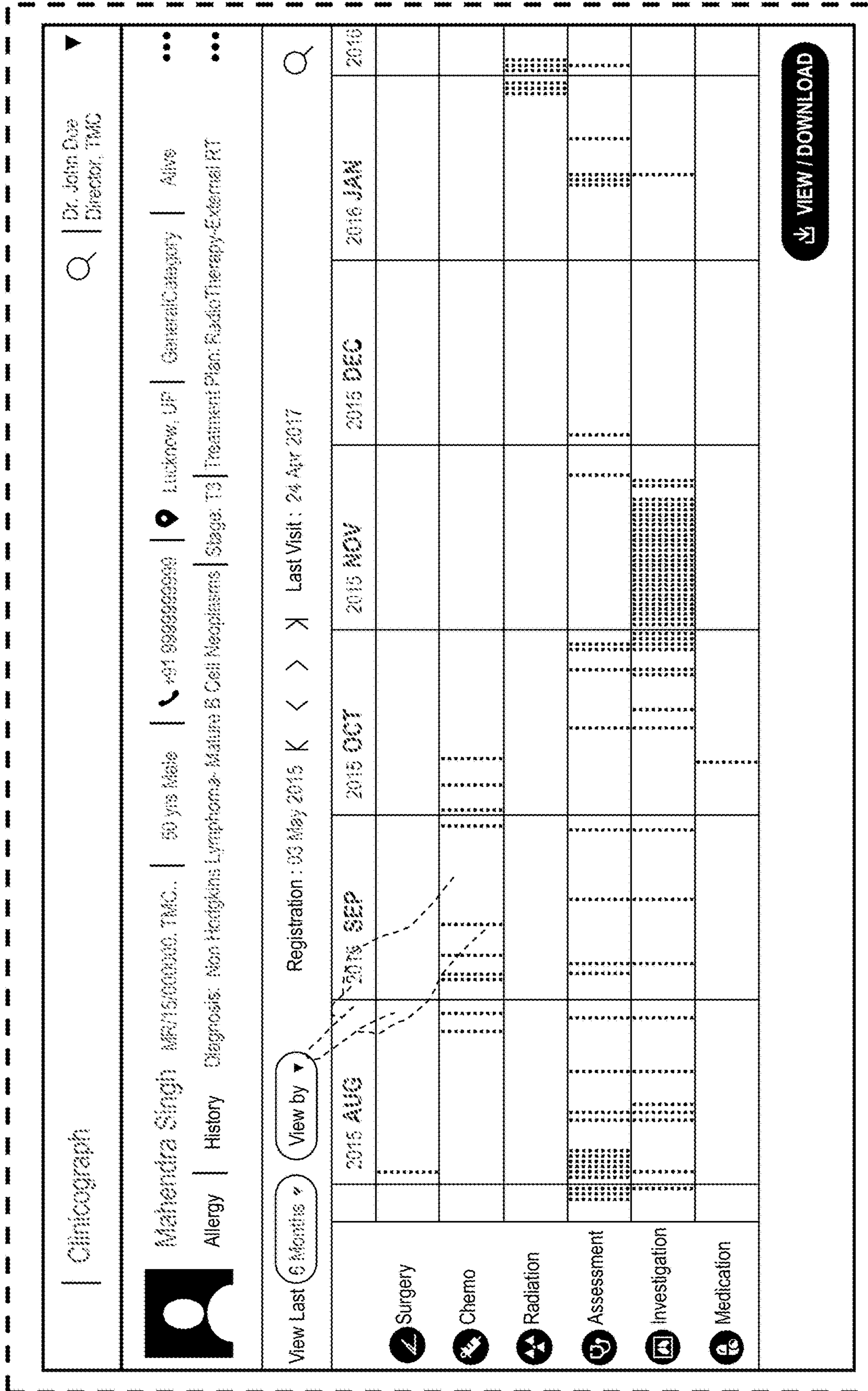


Fig. 6

Clinicograph ▼ Dr. John Dee
Director, FMC

Mahendra Singh MR1500000, M.D. | 60 yrs Male | +91 9999999999 | Locknow, UP | GeneralCategory | Alive

History | Diagnosis: Non Hodgkins Lymphoma- Mature B Cell Neoplasia | Stage: T3 | Treatment Plan: Radio Therapy-External RT

View Last 6 Months | View by | Registration : 03 May 2015 | Last Visit : 24 Apr 2017

Episode Class

- All
- Inpatient
- Outpatient
- Virtual

Provider ID

- All
- Main treating hospital
- Other hospital
- Peripheral clinic
- Network doctor
- DINC

Department

- All
- Clinical Hematology
- Pathology
- Medical Oncology
- Surgical Oncology
- Radiation Oncology

Hide view by Filter

Selected: Virtual Main treating... Surgical Onco... Remove All

| | 2015 AUG | 2015 SEP | 2015 OCT | 2015 NOV | 2015 DEC | 2016 JAN | 2016 FEB |
|----------------------|----------|----------|----------|----------|----------|----------|----------|
| Surgery | | | | | | | |
| Chemo | | | | | | | |
| Radiation | | | | | | | |
| Assessment | | | | | | | |
| Investigation | | | | | | | |
| Medication | | | | | | | |

VIEW / DOWNLOAD

Fig. 7

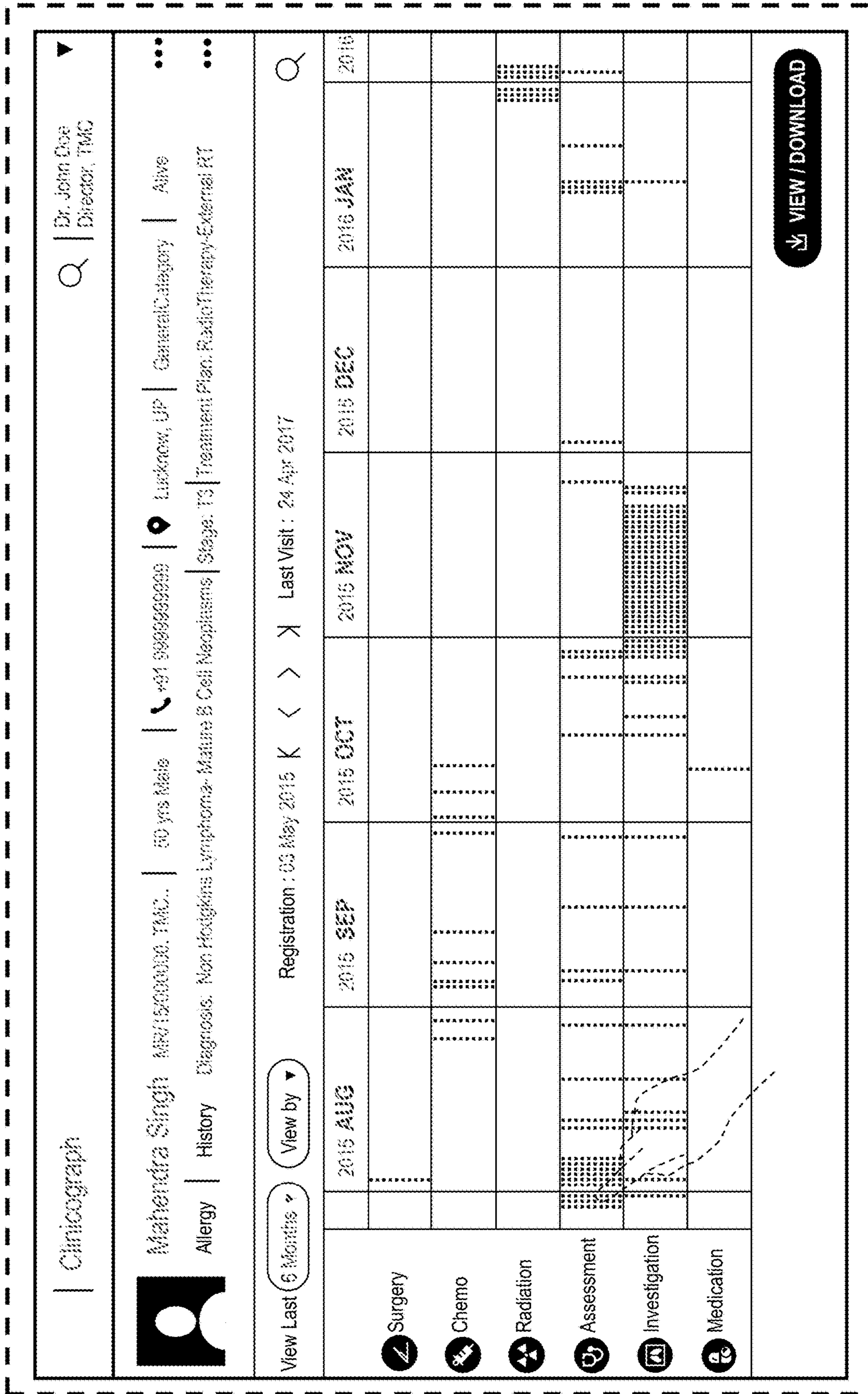


Fig. 8

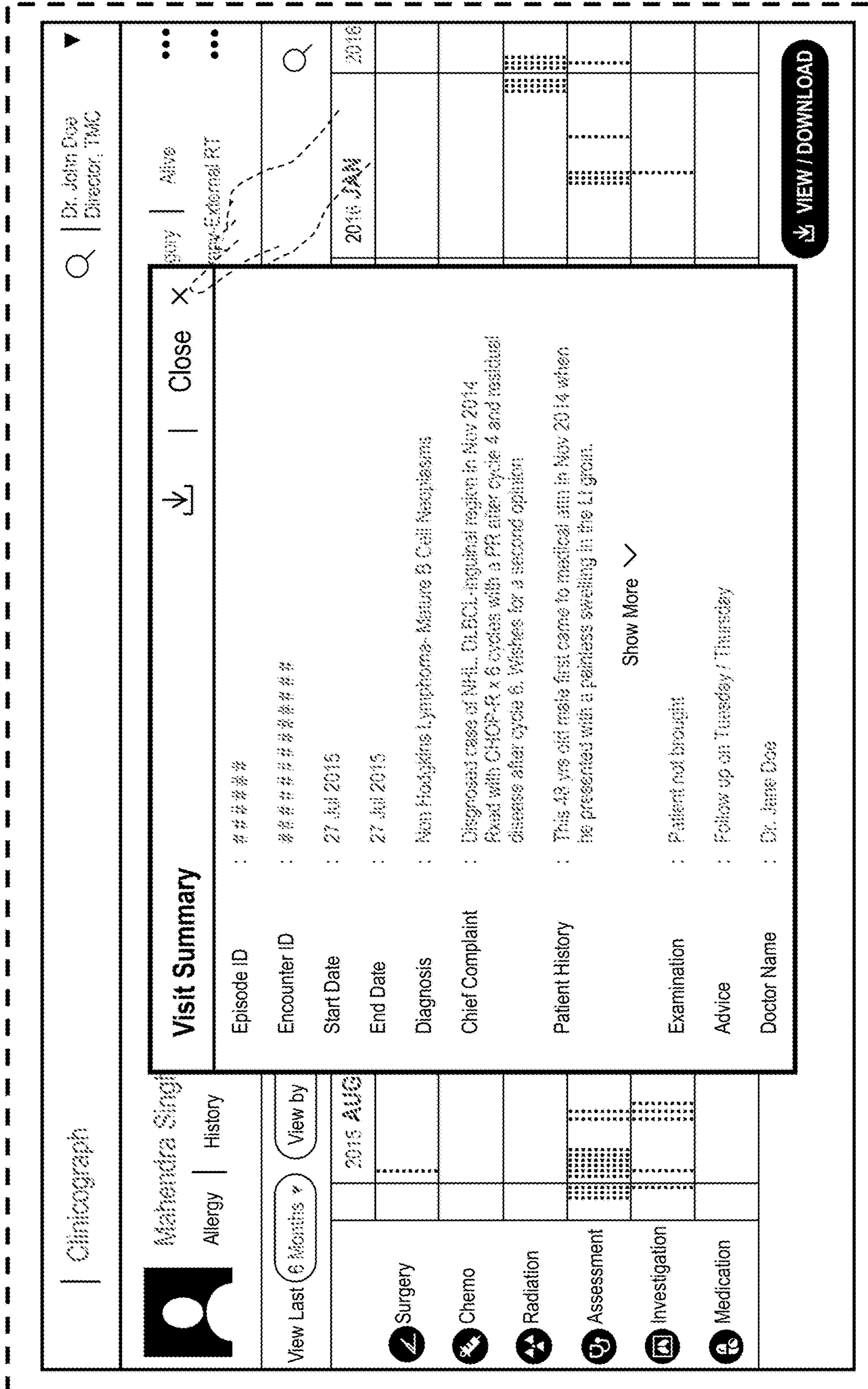


Fig. 9

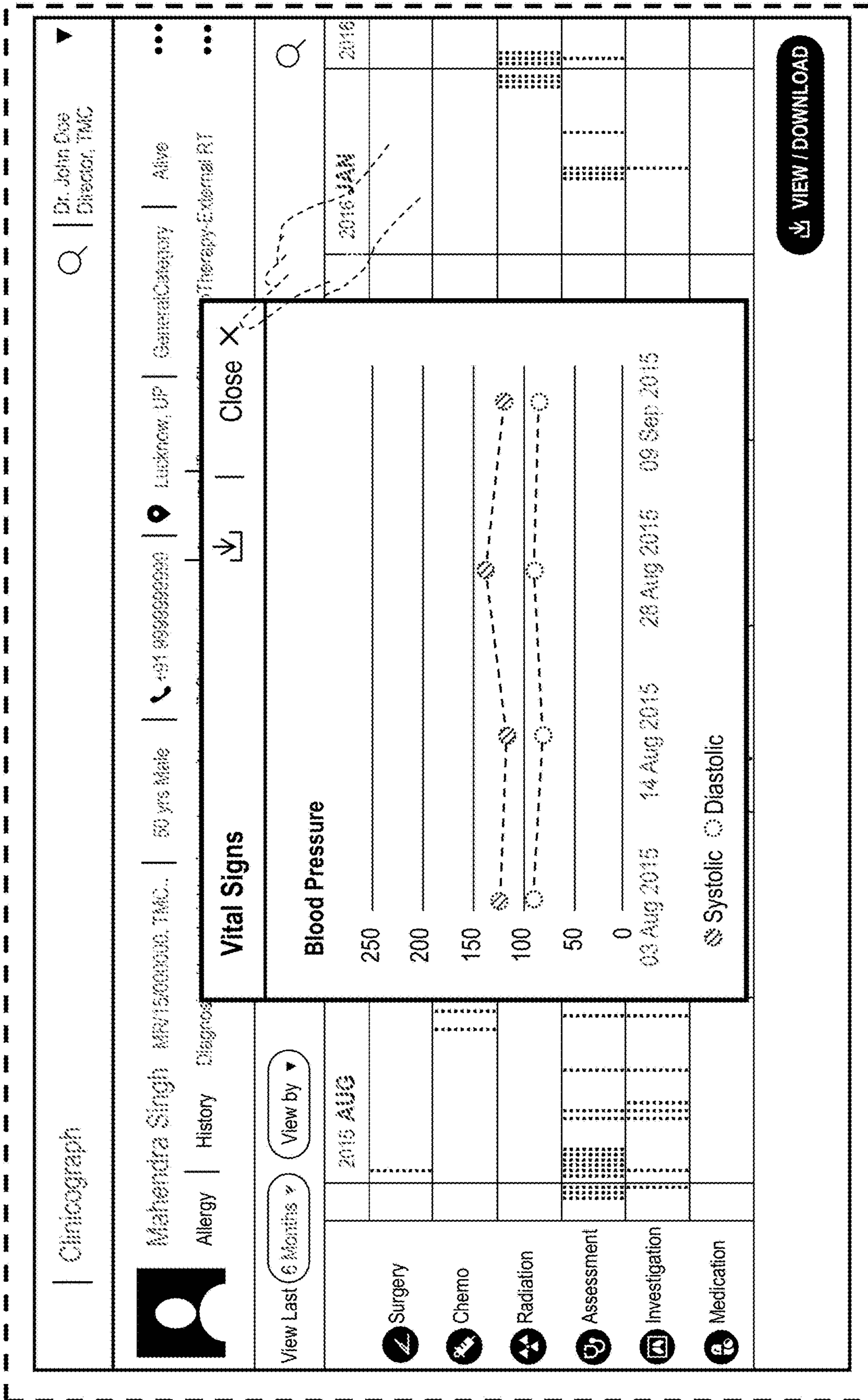



Fig. 10



Clinicograph

Dr. John Doe
Director, TMC

Mahendra Singh MP1500000, TMC. | 50 yrs Male | +91 9999999999 | Lucknow, UP | GeneralCategory | Active







Allergy | History | **Diagnosis**

Therapy-External RT

View Last 6 Months ▼

View by ▼

2015 **AUG**

| | 2015 AUG | 2016 JAN | 2016 JAN | 2016 JAN | 2016 JAN | 2016 JAN |
|--|-----------------|-----------------|-----------------|-----------------|-----------------|-----------------|
|  Surgery  Chemo  Radiation  Assessment  Investigation  Medication | | | | | | |

Investigation Close X

Episode ID : IP715004451

Date : 03 Aug 2015

Test Name : Lymphoma Panel

Specimen : Biopsy

Diagnosis : **CONSISTENT WITH MANTLE CELL LYMPHOMA.**
Favour Plasmocytic variant

Comments : Sections show lymph node with completely effaced architecture by an abnormal infiltrate of neoplastic cells arranged in nodular pattern. The abnormal cells are of medium size with cleaved, pleomorphic nucleus and small nucleoli.

Show More ▼

VIEW / DOWNLOAD

Fig. 11

Clinicograph

Mahendra Singh MR151000000, TMC. | 50 yrs Male | +91 9999999999 | Lucknow, UP | GeneralCategory | Alive

Allergy | History

Dr. John Doe
Director, TMC

View Last 6 Months ▾

2015 **AUG**

- Surgery
- Chemo
- Radiation
- Assessment
- Investigation
- Medication

Compare | Close X

| Date | Investigation Type |
|---|--------------------|
| <input type="checkbox"/> 30 Jul 2015 | X-Ray |
| <input type="checkbox"/> 21 Aug 2015 | Whole Side Image |
| <input type="checkbox"/> 16 Sep 2015 | PET CT |
| <input checked="" type="checkbox"/> 23 Oct 2015 | X-Ray |
| <input checked="" type="checkbox"/> 29 Oct 2015 | X-Ray |

X-Ray Image 1

X-Ray Image 2

External RT

18 JAN 2016

VIEW / DOWNLOAD

Fig. 12

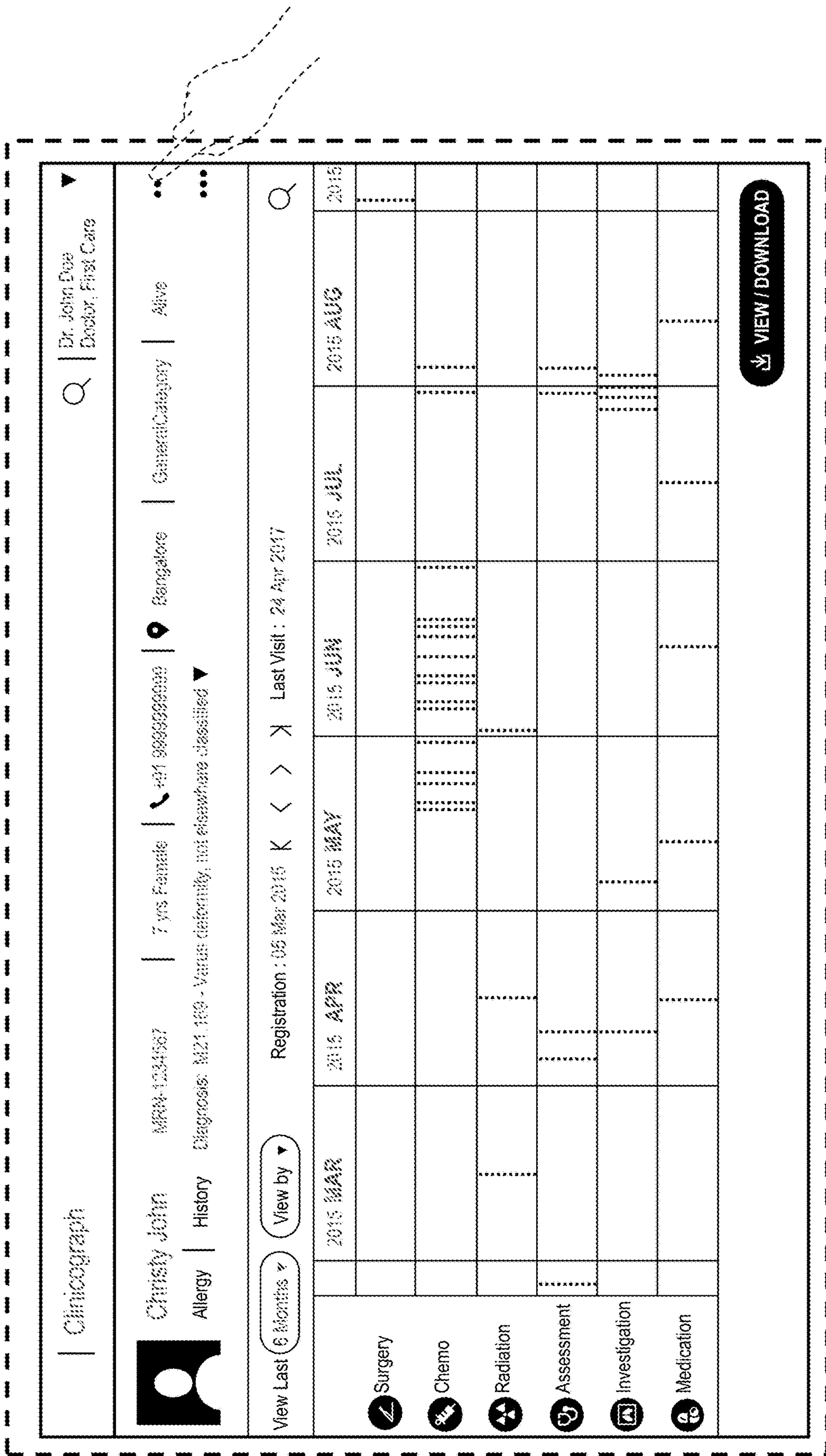


Fig. 13

▼

Dr. John Doe
Doctor, First Care

🔍

Christy John

MRN: 1234567

7 yrs Female

+01 9999999999

Bangalore

General Category

Alive

⋮

⋮

▼

Allergy | History

Diagnosis: M21.109 - Varus deformity, not elsewhere classified

🔍

View Last 6 Months

View by

Registration : 05 Mar 2015

Last Visit : 24 Apr 2017

| | 2015 MAR | 2015 APR | 2015 MAY | 2015 JUN | 2015 JUL | 2015 AUG | 2015 |
|-----------------|----------|----------|----------|----------|----------|----------|------|
| 🔪 Surgery | | | | | | | |
| 🧘 Physiotherapy | | | | | | | |
| 💉 Immunization | | | | | | | |
| 🔬 Investigation | | | | | | | |
| 🗣 Consultations | | | | | | | |
| 💊 Medication | | | | | | | |

📄 VIEW / DOWNLOAD

Fig. 14

Clinicograph

Mehendra Singh MR15000000.TMC. | 50 yrs Male | +01 9999999999 | Lucknow, UP | GeneralCategory | Alive

Allergy | History | Disease

Dr. John Doe
Doctor, First Care

View Last 6 Months

2015 MAR

Medications | Close X

| | | | | | | | |
|-----------|--|--|--|--|--|--|--|
| Emeset | | | | | | | |
| Decdan | | | | | | | |
| Rantac | | | | | | | |
| Pan | | | | | | | |
| Pyrigesic | | | | | | | |

2015 AUG

03 Aug 2015 14 Aug 2015 28 Aug 2015 09 Sep 2015

VIEW / DOWNLOAD

Fig. 15